

## LETTER TO THE EDITOR

### MFN2 mutations cause compensatory mitochondrial DNA proliferation

Kamil S. Sitarz,<sup>1</sup> Patrick Yu-Wai-Man,<sup>1,2</sup> Angela Pyle,<sup>1</sup> Joanna D. Stewart,<sup>1,3</sup>  
 Bernd Rautenstrauss,<sup>4</sup> Pavel Seeman,<sup>5</sup> Mary M. Reilly,<sup>6</sup> Rita Horvath<sup>1,7</sup> and Patrick F. Chinnery<sup>1,7</sup>

1 Wellcome Trust Centre for Mitochondrial Research, Institute of Genetic Medicine, Newcastle University, Newcastle upon Tyne, NE1 3BZ, UK

2 Department of Ophthalmology, Royal Victoria Infirmary, Newcastle upon Tyne, NE1 4LP, UK

3 IfADo – Leibniz Research Centre for Working Environment and Human Factors, Dortmund, Germany

4 Friedrich-Baur Institute, Ludwig Maximilian University, Munich, Germany

5 Department of Child Neurology, DNA Laboratory, Charles University, 2nd School of Medicine and University Hospital Motol, Prague, Czech Republic

6 MRC Centre for Neuromuscular Diseases, UCL Institute of Neurology, Queen Square, London, WC1N 3BG, UK

7 Department of Neurology, Royal Victoria Infirmary, Newcastle upon Tyne, NE1 4LP, UK

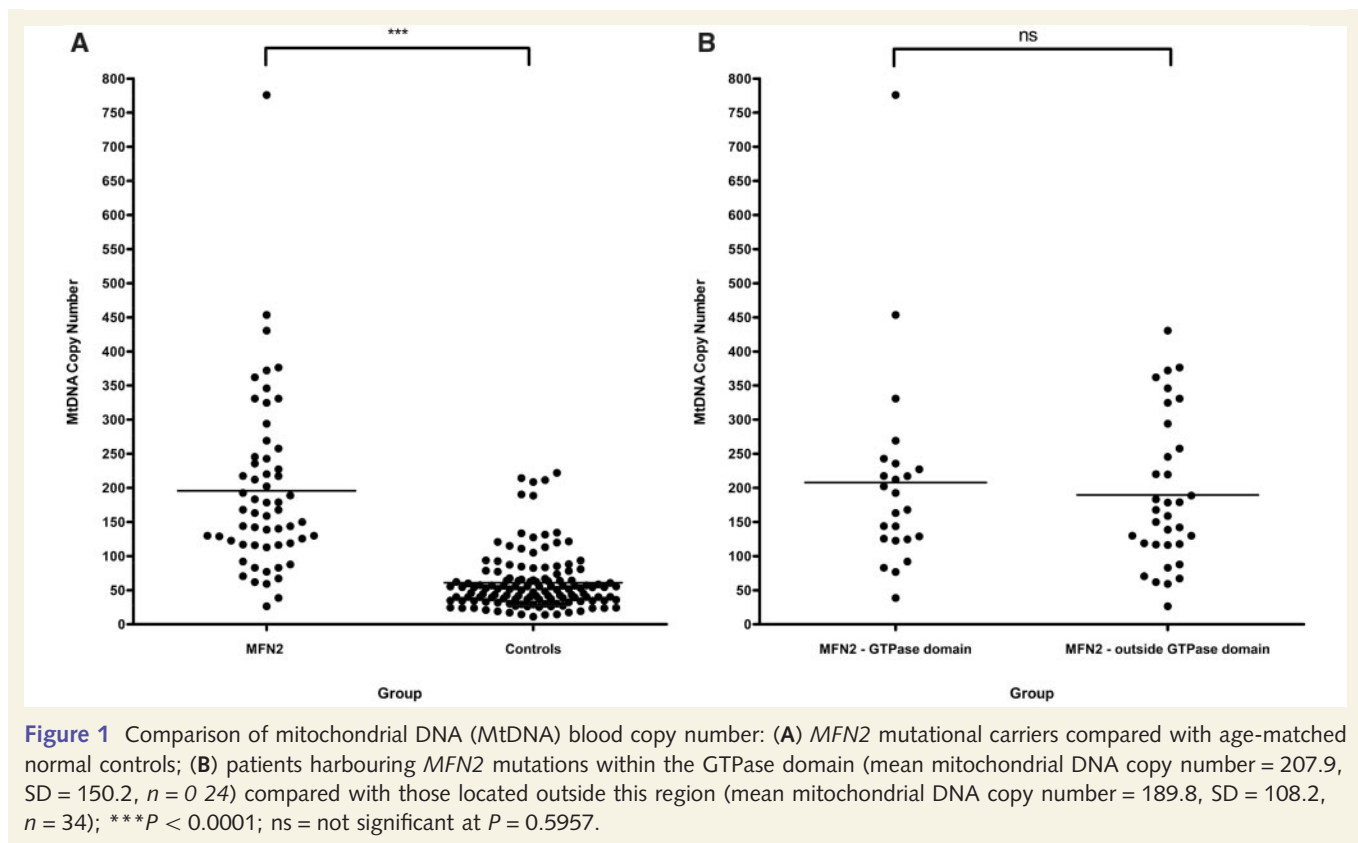
Correspondence to: Dr Patrick Yu-Wai-Man,  
 Wellcome Trust Centre for Mitochondrial Research,  
 Institute of Genetic Medicine,  
 Newcastle University,  
 Newcastle upon Tyne,  
 NE1 3BZ, UK  
 E-mail: patrick.yu-wai-man@ncl.ac.uk

Sir, We read with great interest the report of a Tunisian family by Rouzier *et al.* (2011) describing the neurological disorder linked to a novel heterozygous missense mutation in *MFN2* (1p36.2) (Rouzier *et al.*, 2011). *MFN2* mutations typically cause autosomal dominant axonal Charcot–Marie–Tooth disease (CMT2A, OMIM 609260), with peripheral nerve degeneration occasionally associated with visual failure and optic atrophy (Zuchner *et al.*, 2004, 2006). Interestingly, the clinical manifestations among mutational carriers in this Tunisian family were even more variable, ranging from asymptomatic subclinical disease to an axonal sensorimotor neuropathy complicated by optic atrophy, deafness, cerebellar ataxia and proximal myopathy. Furthermore, the intriguing finding of cytochrome *c* oxidase (COX)-deficient fibres and multiple mitochondrial DNA deletions in skeletal muscle biopsies suggest that *MFN2* mutations can result in disturbed mitochondrial DNA maintenance and an overt respiratory chain defect, in addition to marked fragmentation of the mitochondrial network. These deleterious consequences are strikingly reminiscent of the pathological features recently highlighted in *Brain* for autosomal dominant optic atrophy due to *OPA1* mutations

(Amati-Bonneau *et al.*, 2008; Hudson *et al.*, 2008; Yu-Wai-Man *et al.*, 2010a). Here, we provide additional evidence that *MFN2*-associated neuropathy is a novel disorder of mitochondrial DNA maintenance in a study of 58 probands with CMT2A and confirmed *MFN2* mutations (Table 1), compared with 131 age-matched normal controls.

Total genomic DNA was extracted from the leucocyte fraction of venous blood samples. The average cellular mitochondrial DNA content was quantified with a SYBR Green<sup>TM</sup> quantitative polymerase chain reaction assay on a MyiQ<sup>TM</sup> real-time polymerase chain reaction detection system (Biorad), with *MTND1* as the mitochondrial template and *GAPDH* as the nuclear-encoded housekeeping template (Yu-Wai-Man *et al.*, 2010a). Relative mitochondrial DNA copy number was derived from the difference in threshold cycle ( $C_t$ ) values obtained for *MTND1* and *GAPDH* using the  $2(2^{-\Delta C})$  equation to account for two copies of *GAPDH* per cell nucleus.

Mitochondrial DNA levels in the *MFN2* group [mean mitochondrial DNA copy number = 195.7, standard deviation (SD) = 126.6,  $n = 58$ ] were significantly higher compared with controls (mean mitochondrial DNA copy number = 60.9, SD = 42.3,  $n = 131$ ,



$P < 0.0001$ ) (Fig. 1A). Given the suggestion by Rouzier *et al.* (2011) that *MFN2* mutations involving the functional GTPase domain were more likely to precipitate the severe multi-system phenotype documented in their family, we performed a subgroup analysis based on whether or not patients in our cohort harboured mutations within the highly conserved GTPase gene region. No significant difference was found between these two distinct mutational subgroups ( $P = 0.5957$ ) (Fig. 1B).

Although we have previously shown that variation in the differential blood cell count can affect blood-derived mitochondrial DNA copy number (Pyle *et al.*, 2010), the 3-fold increase in mitochondrial DNA content detected in our *MFN2* cohort was substantially greater than the error attributable to this possible confounding factor. Mitochondrial proliferation is a well-recognized important diagnostic feature in skeletal muscle of patients with a range of mitochondrial cytopathies (Taylor *et al.*, 2004; Aure *et al.*, 2006). This compensatory mechanism is thought to occur in response to an underlying cellular bioenergetic crisis (the 'sick mitochondrion hypothesis'), which leads to the classical 'ragged-red fibre' appearance on Gomori Trichrome or succinate dehydrogenase staining (Chinnery and Samuels, 1999; Capps *et al.*, 2003; Durham *et al.*, 2007). In this study, we have demonstrated the same phenomenon in blood leucocytes derived from patients with *MFN2* mutations. Although Rouzier *et al.* (2011) determined mitochondrial DNA copy number in four

skeletal muscle biopsies, they only report on the absence of mitochondrial DNA depletion in homogenate muscle extracts (Table 1). Pathologically increased mitochondrial DNA levels have been detected in laser-microdissected single skeletal muscle fibres from patients with *OPA1* mutations, this effect being particularly marked in COX-deficient muscle fibres (Yu-Wai-Man *et al.*, 2010b). Given the overlapping clinical, histological and molecular characteristics observed in these two primary disorders of mitochondrial dynamics, it would be of great interest to know whether mitochondrial DNA proliferation was also present in muscle fibres from patients with *MFN2* mutations, especially in the two biopsies noted to have ragged-red fibres.

*MFN2* is the newest member of an expanding group of nuclear mitochondrial disorders characterized by disturbed mitochondrial DNA maintenance, a process which, increasingly, seems to be intrinsically related to the state of the mitochondrial network (Chen *et al.*, 2010; Elachouri *et al.*, 2011). Our observation that *MFN2* mutations cause mitochondrial proliferation in blood adds weight to the novel disease mechanism reported by Rouzier *et al.* (2011). Future work is needed to disentangle the complex interplay between disturbed mitochondrial fusion and fission, mitochondrial DNA instability and the eventual development of both neurological and visual deficits in patients with CMT2A and *MFN2* mutations.

**Table 1** *MFN2* mutations identified in our patient cohort

Mutation	Type	Functional domain	Number of patients
p.Glu65Stop	Nonsense	–	3
p.Arg94Trp	Missense	–	8
p.Arg94Gln	Missense	–	2
p.Ala100Gly	Missense	GTPase	1
p.Arg104Leu	Missense	GTPase	3
p.Arg104Trp	Missense	GTPase	1
p.Thr105Ala	Missense	GTPase	1
p.His165Tyr	Missense	GTPase	6
p.Gly202Ala	Missense	GTPase	4
p.Thr206Ile	Missense	GTPase	2
p.Thr232Asn	Missense	GTPase	1
p.Arg250Gln	Missense	GTPase	1
p.Arg259Cys	Missense	GTPase	1
p.Arg280His	Missense	GTPase	1
p.Gly298Arg	Missense	GTPase	1
p.Glu308Stop <sup>a</sup>	Nonsense	GTPase	1
p.Arg364Trp	Missense	Coiled-Coil 1 (CC1)	1
p.Arg364Pro	Missense	Coiled-Coil 1 (CC1)	1
p.Arg364Gln	Missense	Coiled-Coil 1 (CC1)	1
p.Met376Val	Missense	Coiled-Coil 1 (CC1)	1
p.Met376Ile	Missense	Coiled-Coil 1 (CC1)	1
p.Ala383Val	Missense	Coiled-Coil 1 (CC1)	1
p.Arg468His	Missense	–	2
p.Asp496Gly	Missense	–	2
p.Arg519Pro <sup>a</sup>	Missense	–	1
p.Leu673Pro	Missense	–	3
p.Val705Ile	Missense	Coiled-Coil 2 (CC2)	2
p.Arg707Trp	Missense	Coiled-Coil 2 (CC2)	1
p.Arg707Pro	Missense	Coiled-Coil 2 (CC2)	1
p.Ala716Thr	Missense	Coiled-Coil 2 (CC2)	1
p.His750Pro	Missense	–	1
p.Gln751Stop	Nonsense	–	1
p.Tyr752Stop	Nonsense	–	1

<sup>a</sup>One patient harboured two heterozygous *MFN2* mutations.

## Funding

P.Y.W.M. is a Medical Research Council (MRC, UK) Clinician Scientist. R.H. is supported by the Academy of Medical Sciences (UK) and by the MRC (UK). P.S. is funded by IGA MH CR No 10554-3. P.F.C. is a Wellcome Trust Senior Fellow in Clinical Science and a UK National Institute of Health Senior Investigator who also receives funding from the MRC (UK), Parkinson's UK, the Association Francaise contre les Myopathies, and the UK NIHR Biomedical Research Centre for Ageing and Age-related Disease

award to the Newcastle upon Tyne Hospitals NHS Foundation Trust.

## References

- Amati-Bonneau P, Valentino ML, Reynier P, Gallardo ME, Bornstein B, Boissiere A, et al. *OPA1* mutations induce mitochondrial DNA instability and optic atrophy plus phenotypes. *Brain* 2008; 131: 338–51.
- Aure K, Fayet G, Lacene E, Romero NB, Lombes A. Apoptosis in mitochondrial myopathies is linked to mitochondrial proliferation. *Brain* 2006; 129: 1249–59.
- Capps GJ, Samuels DC, Chinnery PF. A model of the nuclear control of mitochondrial DNA replication. *J Theor Biol* 2003; 221: 565–83.
- Chen HC, Vermulst M, Wang YE, Chomyn A, Prolla TA, McCaffery JM, et al. Mitochondrial fusion is required for mtDNA stability in skeletal muscle and tolerance of mtDNA mutations. *Cell* 2010; 141: 280–9.
- Chinnery PF, Samuels DC. Relaxed replication of mtDNA: a model with implications for the expression of disease. *Am J Hum Genet* 1999; 64: 1158–65.
- Durham SE, Samuels DC, Cree LM, Chinnery PF. Normal levels of wild-type mitochondrial DNA maintain cytochrome c oxidase activity for two pathogenic mitochondrial DNA mutations but not for m.3243A -> G. *Am J Hum Genet* 2007; 81: 189–95.
- Elachouri G, Vidoni S, Zanna C, Pattyn A, Boukhaddaoui H, Gaget K, et al. *OPA1* links human mitochondrial genome maintenance to mtDNA replication and distribution. *Genome Res* 2011; 21: 12–20.
- Hudson G, Amati-Bonneau P, Blakely EL, Stewart JD, He LP, Schaefer AM, et al. Mutation of *OPA1* causes dominant optic atrophy with external ophthalmoplegia, ataxia, deafness and multiple mitochondrial DNA deletions: a novel disorder of mtDNA maintenance. *Brain* 2008; 131: 329–37.
- Pyle A, Burn DJ, Gordon C, Swan C, Chinnery PF, Baudouin SV. Fall in circulating mononuclear cell mitochondrial DNA content in human sepsis. *Intensive Care Med* 2010; 36: 956–62.
- Rouzier C, Bannwarth S, Chaussonot A, Chevrollier A, Verschueren A, Bonello-Palot N, et al. The *MFN2* gene is responsible for mitochondrial DNA instability and optic atrophy 'plus' phenotype. *Brain* 2011; 135: 23–34.
- Taylor RW, Schaefer AM, Barron MJ, McFarland R, Turnbull DM. The diagnosis of mitochondrial muscle disease. *Neuromuscul Disord* 2004; 14: 237–45.
- Yu-Wai-Man P, Griffiths PG, Gorman GS, Lourenco CM, Wright AF, Auer-Grumbach M, et al. Multi-system neurological disease is common in patients with *OPA1* mutations. *Brain* 2010a; 133: 771–86.
- Yu-Wai-Man P, Sitarz KS, Samuels DC, Griffiths PG, Reeve AK, Bindoff LA, et al. *OPA1* mutations cause cytochrome c oxidase deficiency due to loss of wild-type mtDNA molecules. *Human Molecular Genetics* 2010b; 19: 3043–52.
- Zuchner S, De Jonghe P, Jordanova A, Claeys KG, Guergueltcheva V, Cherninkova S, et al. Axonal neuropathy with optic atrophy is caused by mutations in mitofusin 2. *Ann Neurol* 2006; 59: 276–81.
- Zuchner S, Mersyanova IV, Muglia M, Bissar-Tadmouri N, Rochelle J, Dadali EL, et al. Mutations in the mitochondrial GTPase mitofusin 2 cause Charcot-Marie-Tooth neuropathy type 2A. *Nat Genet* 2004; 36: 449–51.