

SHORT REPORT

ABSTRACT: We report a family with X-linked dominant Charcot-Marie-Tooth disease (CMTX1). Three affected family members are described, who underwent detailed clinical, electrophysiological, molecular genetic, and histopathological studies. A novel isoleucine at position 127 with serine (Ile127Ser) mutation in the gap junction protein beta 1 (*GJB1*) gene was detected. The electrophysiological findings were consistent with a primary demyelinating neuropathy with secondary axonal loss and support this model of disease progression. All patients having the CMT phenotype and intermediate conduction velocities who are negative for CMT1A duplication/hereditary neuropathy with liability to pressure palsies (HNPP) deletion, and whose family shows a dominant trait without male-to-male transmission, should be screened for CMTX1.

Muscle Nerve 00: 000–000, 2004

X-LINKED CHARCOT-MARIE-TOOTH DISEASE: PHENOTYPIC EXPRESSION OF A NOVEL MUTATION Ile127Ser IN THE *GJB1* (CONNEXIN 32) GENE

PETR VONDRACEK, MD,¹ PAVEL SEEMAN, MD,² MARKETA HERMANOVA, MD, PhD,³ and LENKA FAJKUSOVA, MD, PhD⁴

¹ Department of Pediatric Neurology, University Hospital and Masaryk University, Cernoplni 9, 625 00 Brno, Czech Republic

² Department of Child Neurology, Second School of Medicine, Charles University and University Hospital Motol, Prague, Czech Republic

³ Department of Pathology, University Hospital and Masaryk University, Brno, Czech Republic

⁴ Department of Molecular Biology and Gene Therapy, University Hospital and Masaryk University, Brno, Czech Republic

Accepted 27 July 2004

X-linked dominant Charcot-Marie-Tooth disease (CMTX1) is an inherited neuropathy caused by mutations affecting the gap junction protein beta 1 (*GJB1*) gene coding for the gap junction protein beta 1 (connexin 32, Cx32), which is located within the Xq13 region. Over 250 different mutations in the *GJB1* (Cx32) gene associated with CMTX1 have been identified.^{1–4,6,9} Males are usually more severely affected and the onset of a motor deficit is earlier than in females. In the pedigree, the affliction is never transmitted from father to son. Motor nerve conduction velocity (NCV) is intermediately slowed in the typical range of 30–38 m/s, but in some female

patients may be near-normal.^{3–7,11} Conduction velocities in the 20 m/s range are extremely rare in CMTX1 patients and can electrophysiologically distinguish CMTX1 from CMT type 1. Subclinical central nervous system (CNS) involvement indicated by changes in visual evoked potentials (VEPs) or brainstem auditory evoked potentials (BAEPs) have been described.^{1,9,12}

There is still confusion as to whether CMTX1 is primarily an axonal or demyelinating neuropathy.^{3,5–8} We report a family with CMTX1 as an example of how the genetic defect of connexin 32 affects first myelin and then leads to axonal degeneration, and discuss the clinical consequences of this process.

PATIENTS AND METHODS

Family Data. We studied a three-generation family with one affected member in each generation. Peripheral neuropathy was found to be a familial trait on the maternal side of the pedigree (Fig. 1). Two healthy siblings from two generations were also studied (individuals 4 and 5). Clinical presentations were very similar in all affected members: the proband, a

Abbreviations: BAEPs, brainstem auditory evoked potentials; CMAP, compound muscle action potential; CMTX1, Charcot-Marie-Tooth disease; CNS, central nervous system; Cx32, connexin 32; EMG, electromyography; *GJB1*, gap junction protein beta 1; HNPP, hereditary neuropathy with liability to pressure palsies; Ile, isoleucine; MRI, magnetic resonance imaging; NCV, nerve conduction velocity; PCR, polymerase chain reaction; Ser, serine; *SMN1*, survival motor neuron 1; VEPs, visual evoked potentials

Key words: Charcot-Marie-Tooth disease; CMTX1; connexin 32; gap junction protein beta 1; hereditary motor and sensory neuropathy; X-linked

Correspondence to: P. Vondracek; e-mail: pvondracek@fnbrno.cz

© 2004 Wiley Periodicals, Inc.
Published online 00 Month 2004 in Wiley InterScience (www.interscience.wiley.com). DOI 10.1002/mus.20166

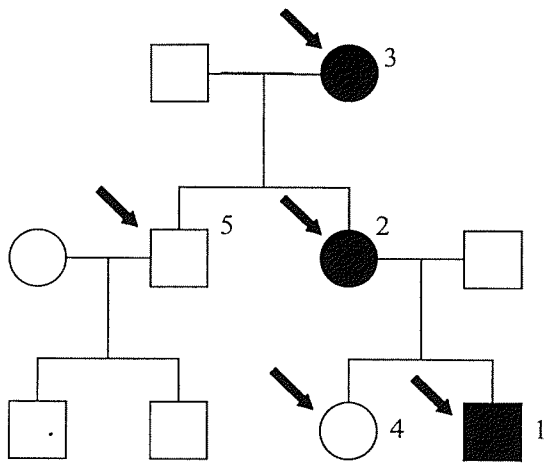


FIGURE 1. Family pedigree. Empty circles indicate unaffected females; empty squares, unaffected males; filled circles, affected females; filled squares, affected males. DNA analysis was performed for patients marked with arrows.

13-year-old boy (patient 1), his mother (age 32; patient 2), and maternal grandmother (age 56; patient 3). They displayed distal muscle weakness, peroneal muscle atrophy, inability to walk on the heels, areflexia, and discrete distal sensory disturbance. The women were mildly affected and had no foot deformities. The boy had more severe weakness and pes equinovarus. He had an early onset of walking difficulties in infancy, whereas clinical symptoms in his mother and grandmother did not develop until the end of the second decade. None of them had any clinical signs of CNS involvement.

Methods. The study was approved by the local ethics committee. All three affected and the two unaffected family members were examined both clinically and electrophysiologically. Motor and sensory nerve conduction studies and needle electromyography of the first dorsal interosseous, tibialis anterior, and vastus lateralis muscles were performed according to standard procedures using a Nicolet Viking IV (Nicolet Biomedical, Madison, Wisconsin). Normal limits from our laboratory were used for comparison.

Molecular genetic studies were performed on all family members. DNA was extracted from leukocytes using a standard method after informed consent had been obtained. Initially, the CMT1A duplication on chromosome 17p11.2 was excluded with a set of 15 polymorphic microsatellite markers.¹⁰ Testing for deletions in survival motor neuron 1 (*SMN1*) gene was performed by polymerase chain reaction (PCR) and restriction digestions, using the technique described by van der Steege.¹³ Molecular diagnosis of

CMTX was accomplished by direct sequencing of the entire coding region of the *GJB1* gene. PCR product containing the only coding exon 2 of the *GJB1* gene was directly sequenced in two fragments using the Big Dye Terminator Ver. 3.1. kit (ABI, Foster City, California) and analyzed on a capillary Genetic Analyzer ABI3100Avant (ABI).

Visual and brainstem auditory evoked potentials (VEPs and BAEPs) were performed in the two affected women and one unaffected sibling. Patient 2 underwent magnetic resonance imaging (MRI) of the brain, which was normal. A sural nerve biopsy was also performed in this patient with her informed consent. Chrome-osmium fixation was used and the specimen was embedded in Epon 812-Durcupan ACM (Fluka, Buchs, Switzerland; Serva, Heidelberg, Germany). Semi-thin sections (0.1 μm) were mounted on slides and stained with methylene blue-azure II-basic fuchsin.

RESULTS

Electrodiagnostic Examination. The main conduction findings are summarized in Table 1. Needle electromyography (EMG) revealed a profound chronic axonopathy with sporadic fibrillation potentials and long-duration polyphasic motor unit potentials, corresponding to a reinnervation process. These findings were prevalent in peroneal muscles and considerably more severe in both older women than in the young boy. In clinically unaffected relatives, all conduction and EMG parameters were normal.

VEPs were normal in all tested individuals. BAEPs were normal in the unaffected brother of patient 2, whereas findings in both women were abnormal. In patient 2, delayed III-V interpeak intervals (2.73 ms left, 2.79 ms right, upper normal limit 2.4 ms) and I-V interpeak intervals (4.92 ms left, 4.89 ms right, upper normal limit 4.5 ms) were recorded. In patient 3, the recorded data were similar. These findings reflect abnormal central conduction in the brainstem.

Molecular Genetic Studies. The CMT1A duplication on chromosome 17p11.2 and deletions in *SMN1* gene were excluded as a first step. Direct sequencing of the *GJB1* (Cx32) gene then showed a homozygous T-to-G missense mutation at nucleotide position 380 in exon 2, resulting in the substitution of isoleucine at position 127 with serine (Ile127Ser) in patient 1. The same mutation, but in heterozygous state, was detected in affected females of the family (patients 2 and 3). This base change cosegregated with all af-

Table 1. Electrophysiological studies in affected members of the family with a novel Ile127Ser mutation in the *GJB1* (Cx32) gene.

Variable	Nerve	Normal limits	Patient		
			1	2	3
Distal latencies (ms)	Median	4.3	4.8	5.4	5.8
	Peroneal	4.7	Absent	Absent	Absent
	Tibial	5.2	5.8	Absent	Absent
Motor NCVs (m/s)	Median	47	33	37	38
	Peroneal	45	Absent	Absent	Absent
	Tibial	41	36	Absent	36
Sensory NCVs (m/s)	Ulnar	52	39	36	40
	Sural	47	41	Absent	Absent
	Median	4.0	5.9	1.7	1.5
CMAP amplitudes (mV)	Peroneal	2.0	Absent	Absent	Absent
	Tibial	2.5	1.6	Absent	0.7
	Ulnar	7.8	2.0	2.9	2.0
SNAP amplitudes (μ V)	Sural	4.2	4.0	Absent	Absent

CMAP, compound muscle action potential; NCV, nerve conduction velocity; SNAP, sensory nerve action potential.

affected members of the family and was not present in unaffected members of the family, or in 50 normal female control DNA samples. To the best of our knowledge, this mutation had not previously been reported.

Biopsy. Sural nerve biopsy in patient 2 showed marked loss of myelinated fibers and a few clusters of regenerating axons. The main histopathological feature was the presence of onion-bulb formations. Axonal atrophy, degeneration, and loss of myelinated nerve fibers were revealed. These findings suggested that both a demyelination and an axonal loss were present in this patient. There was a pronounced thickening of the perineurium and no inflammatory infiltration. These findings are consistent with an inherited, predominantly demyelinating neuropathy.

DISCUSSION

This CMTX1 family had a novel Ile127Ser mutation in the *GJB1* (Cx32) gene. The affected boy had an earlier onset of symptoms and more severe phenotype than his female relatives. Electrophysiological studies showed intermediately slowed motor NCVs. Compound muscle action potential (CMAP) amplitudes were significantly lower in the older women than young boy, which suggested an age-related loss of motor axons. In addition to nerve conduction studies, we performed needle EMG, which revealed signs of a severe chronic axonopathy with reinnervation. The abnormalities in the boy were consistent with a diffuse motor and sensory demyelinating neuropathy, whereas in the older women a profound chronic axonopathy prevailed and apparently masked the underlying defect of myelin.

The sural nerve biopsy in our patient with Ile127Ser mutation showed marked axonal loss and numerous onion-bulb formations as the sign of Schwann cell pathology. Our findings are consistent with the hypothesis that the phenotypic features of CMTX1 are mainly caused by an age-related loss of large myelinated axons.

Our impression is that CMTX1 patients initially develop a demyelinating neuropathy, followed by a slowly progressive axonopathy. The disease is primarily caused by Schwann cell pathology which ultimately leads to axonal damage. Our results indicate that conduction is first slowed and then the axon degenerates, and as such it is likely that the mutation affects myelin and then leads to secondary axonal degeneration. Although this has been alluded to in previous studies, our electrophysiological and histopathological findings support this model of disease progression.

All patients with the CMT phenotype and intermediate slowing of conduction velocities who are negative for CMT1A duplication/hereditary neuropathy with liability to pressure palsies (HNPP) deletion, and whose family shows a dominant trait without male-to-male transmission, should be screened for mutations in the *GJB1* (Cx32) gene.

The study was supported by the Internal Grant Agency of the Ministry of Health of the Czech Republic with grants IGANF6504, VZ1113000, and CEZ MZ/98/0001/00209627.

REFERENCES

1. Bahr M, Andres F, Timmerman V, Nelis ME, Van Broeckhoven C, Diehgans J. Central visual, acoustic, and motor pathway involvement in a Charcot-Marie-Tooth family with an

- Asn205Ser mutation in the connexin 32 gene. *J Neurol Neurosurg Psychiatry* 1999;66:202-206.
- Birouk N, Le Guern E, Maisonobe T, Rouger H, Gouider R, Tardieu S, Gugenheim M, Routon MC, Leger JM, Agid Y, Brice A, Bouche P. X-linked Charcot-Marie-Tooth disease with connexin 32 mutations. *Neurology* 1998;50:1074-1082.
 - Gutierrez A, England JD, Sumner AJ, Ferer S, Warner LE, Lupski JR, Garcia CA. Unusual electrophysiological findings in X-linked dominant Charcot-Marie-Tooth disease. *Muscle Nerve* 2000;23:182-188.
 - Kuntzer T, Dunand M, Schorderet DF, Vallat JM, Hahn AF, Bogousslavsky J. Phenotypic expression of a Pro 87 to Leu mutation in the connexin 32 gene in a large Swiss family with Charcot-Marie-Tooth neuropathy. *J Neurol Sci* 2003;207:77-86.
 - Lewis RA. The challenge of CMTX and connexin 32 mutations. *Muscle Nerve* 2000;23:147-149.
 - Lewis RA, Shy ME. Electrodiagnostic findings in CMTX: a disorder of the Schwann cell and peripheral nerve myelin. *Ann NY Acad Sci* 1999;883:504-507.
 - Lewis RA, Sumner AJ, Shy ME. Electrophysiological features of inherited demyelinating neuropathies: a reappraisal in the era of molecular diagnosis. *Muscle Nerve* 2000;23:1472-1487.
 - Scherer SS, Fischbeck KH. Is CMTX an axonopathy? *Neurology* 1999;52:432-433.
 - Seeman P, Mazanec R, Cvrteckova M, Smilkova D. Charcot-Marie-Tooth type X: a novel mutation in the Cx32 gene with central conduction slowing. *Int J Mol Med* 2001;8:461-468.
 - Seeman P, Mazanec R, Zidar J, Hrusakova S, Cvrteckova M, Rautenstrauss B. Charcot-Marie-Tooth disease type 1A (CMT1A) and hereditary neuropathy with liability to pressure palsies (HNPP): reliable detection of the CMT1A duplication and HNPP deletion using 8 microsatellite markers in 2 multiplex PCRs. *Int J Mol Med* 2000;6:421-426.
 - Tabaraud F, Lagrange E, Sindou P, Vandenberghe A, Levy N, Vallat JM. Demyelinating X-linked Charcot-Marie-Tooth disease: unusual electrophysiological findings. *Muscle Nerve* 1999;22:1442-1447.
 - Taylor RA, Simon EM, Marks HG, Scherer SS. The CNS phenotype of X-linked Charcot-Marie-Tooth disease: more than a peripheral problem. *Neurology* 2003;61:1475-1478.
 - Van der Steege G, Grootsholten PM, van der Vlies P, Draaijers TG, Osinga J, Cobben JM, Scheffer H, Buys CH. PCR-based DNA test to confirm clinical diagnosis of autosomal recessive spinal muscular atrophy. *Lancet* 1995;15:45:985-986.