

Review

Orphan Peripheral Neuropathies

Josef Finsterer^{a,*}, Wolfgang N. Löscher^b, Julia Wanschitz^b and Stefan Iglseider^c

^a*Klinik Landstrasse, Messerli Institute, Vienna, Austria*

^b*Department of Neurology, Medical University, Innsbruck, Austria*

^c*Konventhospital Barmherzige Brüder, Linz, Austria*

Abstract.

Objectives: Generally, neuropathies of peripheral nerves are a frequent condition (prevalence 2–3%) and most frequently due to alcoholism, diabetes, renal insufficiency, malignancy, toxins, or drugs. However, the vast majority of neuropathies has orphan status. This review focuses on the etiology, frequency, diagnosis, and treatment of orphan neuropathies.

Methods: Literature review

Results: Rareness of diseases is not uniformly defined but in the US an orphan disease is diagnosed if the prevalence is <1:200000, in Europe if <5:10000. Most acquired and hereditary neuropathies are orphan diseases. Often the causative variant has been reported only in a single patient or family, particularly the ones that are newly detected (e.g. *SEPT9*, *SORD*). Among the complex neuropathies (hereditary multisystem disorders with concomitant neuropathies) orphan forms have been reported among mitochondrial disorders (e.g. NARP, MNGIE, SANDO), spinocerebellar ataxias (e.g. *TMEM240*), hereditary spastic paraplegias (e.g. *UBAP1*), lysosomal storage disease (e.g. Schindler disease), peroxisomal disorders, porphyrias, and other types (e.g. giant axonal neuropathy, Tangier disease). Orphan acquired neuropathies include the metabolic neuropathies (e.g. vitamin-B1, folic acid), toxic neuropathies (e.g. copper, lithium, lead, arsenic, thallium, mercury), infectious neuropathies, immune-mediated (e.g. Bruns-Garland syndrome), and neoplastic/paraneoplastic neuropathies.

Conclusions: Though orphan neuropathies are rare per definition they constitute the majority of neuropathies and should be considered as some of them are easy to identify and potentially treatable, as clarification of the underlying cause may contribute to the knowledge about etiology and pathophysiology of these conditions, and as the true prevalence may become obvious only if all ever diagnosed cases are reported.

Keywords: Neuropathy, peripheral nerves, orphan diseases, hereditary, sensory, motor, nerve conduction velocity

ABBREVIATIONS

AD	Autosomal dominant
AHSCT	Allogenic hematopoietic stem cell transplantation
AIDP	Acute inflammatory demyelinating polyneuropathy
AR	Autosomal recessive
ASCT	Autologous stem cell transplantation
BGS	Bruns Garland syndrome

CANOMAD	Chronic ataxic neuropathy with ophthalmoplegia, M-proteins, cold agglutinins and disialosyl antibodies
CANVAS	Cerebellar ataxia, neuropathy, vestibular areflexia syndrome
CASPR-1	Contactin-associated protein-1
CIDP	Chronic, inflammatory demyelinating polyneuropathy
CIPN	Chemotherapy-induced polyneuropathy
CMT	Charcot-Marie-Tooth
CNS	Central nervous system
CNTN-1	Contactin-1

*Correspondence to: Josef Finsterer, MD, PhD, Postfach 20, 1180 Vienna, Austria, Europe. Tel.: +43 1 71165 72085; Fax: +43 1 71165; E-mail: fifigs1@yahoo.de.

DADS	Distal, acquired, demyelinating, symmetric neuropathy
EGPA	Eosinophilic granulomatosis with polyangitis
EHE	Epithelioid hemangio-endothelioma
FRDA	Friedreich ataxia
GAN	Giant axonal neuropathy
GBS	Guillain-Barre syndrome
GFAP	Glial fibrillary acidic protein
HDL	High density lipoprotein
HMN	Hereditary motor neuropathy
HMSN	Hereditary motor and sensory neuropathy
HNA	Hereditary neuralgic amyotrophy
HNPP	Hereditary neuropathy with liability to pressure palsies
HSAN	Hereditary sensory and autonomic neuropathy
HSP	Hereditary spastic paraplegia
IF	Intermediate filaments
LFN	Large-fiber neuropathy
LSDs	Lysosomal storage disorders
MADSAM	Multifocal acquired demyelinating sensory and motor
MAG	Myelin associated glycoprotein
MID	Mitochondrial disorder
MFS	Miller-Fisher syndrome
MEMSA	Myoclonus epilepsy, myopathy, and sensory ataxia
MGUS	Monoclonal gammopathy of unknown significance
MMN	Multifocal motor neuropathy
MNGIE	Mitochondrial neuropathy, gastrointestinal encephalopathy
MT	Maternal transmission
NARP	Neuropathy, ataxia, retinitis pigmentosa
NCS	Nerve conduction study
NF-155	Neurofascin-155
NGS	Next generation sequencing
NSVN	Non-systemic, vasculitic neuropathy
PME	Progressive myoclonus epilepsy
PNP	Polyneuropathy
PNS	Peripheral nervous system
POEMS	Polyneuropathy, organomegaly, endocrinopathy, monoclonal protein, skin changes
SANDO	Sensory ataxic neuropathy with dysarthria and ophthalmoparesis
SCA	Spinocerebellar ataxia
SCAE	Spinocerebellar ataxia with epilepsy

SCLC	Small cell lung carcinoma
SFN	Small fiber neuropathy
SSN	Subacute sensory neuropathy
SSR	Sympathetic skin response
TTR	Transthyretin-related
VEGF	Vascular endothelial growth factor
WES	Whole exome sequencing
XL	X-linked

INTRODUCTION

Generally, neuropathies of peripheral nerves are a highly prevalent neurological problem, due to the high prevalence of diabetes, alcoholism, and renal insufficiency [1]. The remaining neuropathies are rare and there are a number of neuropathies, which have been only reported in a few patients or a single patient (orphan neuropathies). Concerning these rare neuropathies, prevalence figures are hardly available and often questionable due to limited coverage of a region or insufficient work-up or cooperation between centres. Generally, rare neuropathies occur among all subtypes, hereditary and acquired (metabolic, immune, neoplastic, infectious, toxic). This review focuses on recent advances concerning the etiology, clinical presentation, diagnosis, treatment (if available), and outcome of rare neuropathies of peripheral nerves.

DEFINITION OF RARENESS

The term “rare” is poorly defined in Medicine. It may implicate that only a “few” cases have been reported worldwide so far or it may implicate that the condition can be hardly found in a particular region but may occur with a much higher frequency in another region. Subjectively, a rare disease may be one that an individual physician has not encountered during his practice yet but this depends strongly on the duration of his experience and the setting he is working in. Quantitatively, rareness of a disease can be defined as a disorder with <10 hits on a broad PubMed search. With regard to prevalence rareness is defined as neuropathy occurring in less than 1:10000 subjects. The definition of an orphan disease is not uniform and varies from country to country [2]. Figures vary from 1:1000 to 1:200000 (e.g. USA) people nationwide [3]. In Europe, orphan diseases are those with a prevalence of <5:10000. Ultra-rare diseases have a prevalence of <1:50000. It is estimated that there

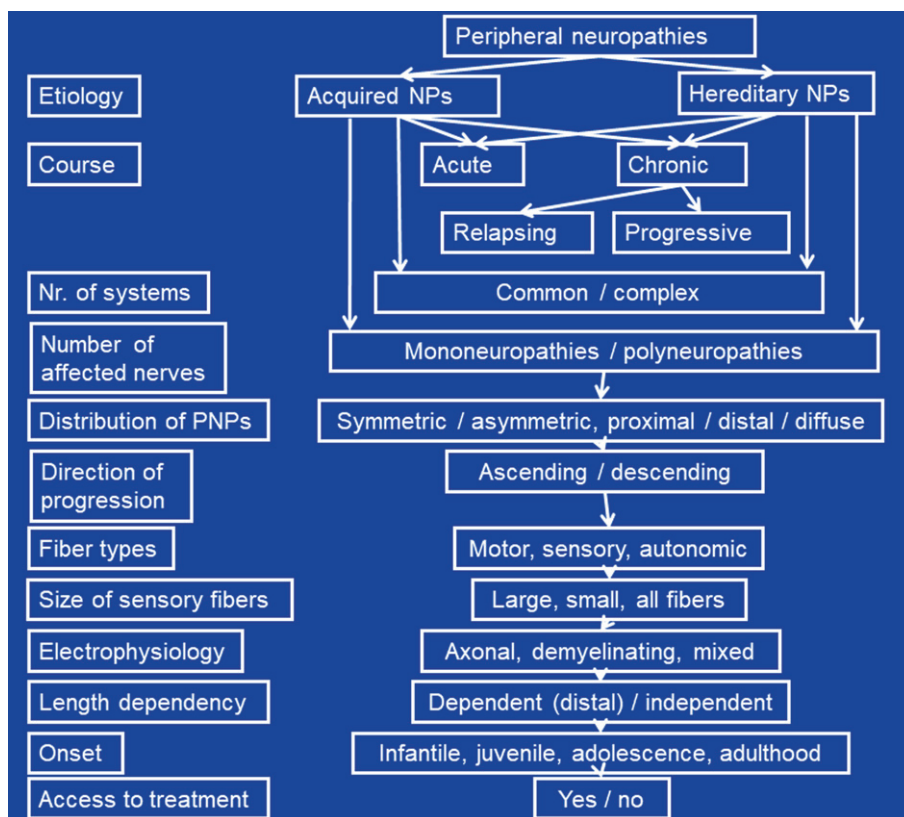


Fig. 1. Classification of orphan peripheral neuropathies according to various criteria.

are about 6000 (5000–7000) orphan diseases [3]. For the majority of rare neuropathies, figures about the true prevalence and incidence are unavailable. Thus, frequency figures largely rely only on estimations [4].

CLASSIFICATION OF NEUROPATHIES

Neuropathies of peripheral nerves may be classified according to various criteria (Fig. 1). The most important classification is the one according to the etiology, which differentiates between acquired or inherited forms. Among acquired and hereditary neuropathies further subdivision have been proposed (see below). Acquired and hereditary neuropathies are classified according to the course as acute or chronic. Acquired and hereditary neuropathies may be accompanied by involvement of other systems/organs/tissues or not. The latter are further classified according to the degree of co-affected of other organs or tissues as dominant or non-dominant. In non-dominant cases, neuropathy is overshadowed

by manifestations of other organs. The course may be chronic progressive or relapsing remitting (Tangier's disease, porphyrias). Progressive neuropathies may be slowly or rapidly progressive. According to the number of affected nerves, mono-neuropathies and polyneuropathies (PNPs) are distinguished. Among PNPs those with uniform affection of all nerves and those with predominant affection of several single nerves (multiplex neuropathy) are differentiated. PNPs are further classified according to the distribution as symmetric or asymmetric and as proximal or distal. Furthermore, neuropathies of the cranial nerves and the peripheral nerves are delineated. According to the direction of progression neuropathies can be ascending or descending. According to the types of nerve fibers affected they may be classified as motor, sensory, autonomic, or mixed neuropathies. According to the size of affected fibers, large- and small-fiber neuropathies (LFNs, SFNs) are delineated. Upon electrophysiological findings, axonal, demyelinating (with or without conduction block), or mixed neuropathies are

differentiated. According to the prevalence, they may be classified as frequent or infrequent (rare). Neuropathies can be painful or painless. Neuropathies can be length-dependent (i.e. distal, the longer the more severe, dying-back), which is the case for most of the neuropathies, or length-independent. Lastly, neuropathies may have an infantile/childhood onset or may have an onset in adolescence/adulthood. Some neuropathies may be accessible to treatment, others may not.

FREQUENCY OF PNPS

It is estimated that the prevalence of peripheral neuropathies is 2–3% in the general population [5]. However, in patients >55 y of age the prevalence increases to 8% [5]. Most of the neuropathies of undetermined cause are rare neuropathies but many of the acquired and hereditary neuropathies are rare either. Exact prevalence/incidence data about rare neuropathies are hardly available. In the rare case that prevalence/incidence data about neuropathies are available, they are representative only for a certain region but usually not for a nation, a continent, or the globe. Low prevalence data may result from inadequate effort to detect the cause or insufficient tools to search for the etiology. For example, transthyretin-related (TTR)-amyloid neuropathy is infrequent (estimated world-wide prevalence: >10000) because it may remain undetected for some time as long as TTR is considered as a differential diagnosis of neuropathy of undetermined cause. The prevalence of TTR-amyloid neuropathy is 22.93/100000 in Portugal [6], 8.7–11/100000 in Japan [7], and 91–104/100000 in Sweden [8]. The prevalence of chronic, inflammatory demyelinating polyneuropathy (CIDP) is calculated as 2.8–3.0/100000.

DIAGNOSIS OF PERIPHERAL NEUROPATHIES

Multiple algorithms for diagnostic work-up of neuropathies are available [9]. They all rely on the history, clinical exam, blood tests, NCSs, CSF investigations, imaging, biopsy and genetic investigations. Selection of laboratory investigations is variable, depending on the clinical presentation, availability, costs, and expertise of the referring neurologist. Generally, answers to the questions “what” (which nerve fiber modalities are involved), “where” (which are the complaints), “when” (which

is the temporal evolution), and “which setting” (unique clinical circumstances of a patient) should be obtained to classify the type of neuropathy [5]. For work-up of hereditary neuropathies, it is crucial that a thorough individual and family history is taken and that apparently asymptomatic family members are seen by the managing physician for subclinical weakness, wasting, or foot deformities, since the affected subject may not recognise subtle deficiencies himself. As soon as hereditary neuropathy is suspected, genetic work-up (e.g. multigene panel, next generation sequencing (NGS)) should be initiated. NGS has the disadvantage that it does not reliably detect duplications or deletions, splice-site variants, or intronic variants and is difficult to interpret in the context of non-specific point mutations (variants of unknown significance) with oligogenic inheritance [10]. Additionally, NGS has a cost-depth trade-off [10], that is, it can screen a small number of genes with good read depth or a large number with less depth [10]. A list of Charcot-Marie-Tooth (CMT) genes can be accessed via the inherited neuropathy variant browser (<http://hihg.med.miami.edu/neuropathybrowser>). Work-up for SFNs relies on skin biopsy as golden standard but can be supported by quantitative sensory testing, electrophysiology, and the skin-responsive Sudoscan®. After diagnosing SFN, work-up for the underlying cause must follow. In patients with prominent muscle atrophy but little muscle weakness or sensory deficits and preserved tendon reflexes, a vascular neuropathy should be considered. In asymmetric PNPs an infectious, immune-mediated, or neoplastic etiology should be considered. Nerve biopsy is indicated for vasculitis, amyloidosis, sarcoidosis, or leprosy, but may be helpful also for CIDP. A proposal for the diagnostic work-up of orphan neuropathies is provided in Fig. 2.

ACQUIRED NEUROPATHIES

Acquired neuropathies include the metabolic, toxic, infectious, immune-mediated, and neoplastic/paraneoplastic neuropathies [5]. As with hereditary neuropathies, acquired neuropathies can be the exclusive manifestation of a disease or may occur together with affection of other organs. The majority of acquired neuropathies is frequently diagnosed but some have to be assessed as rare. Generally, acquired neuropathies are more frequent than hereditary neuropathies.

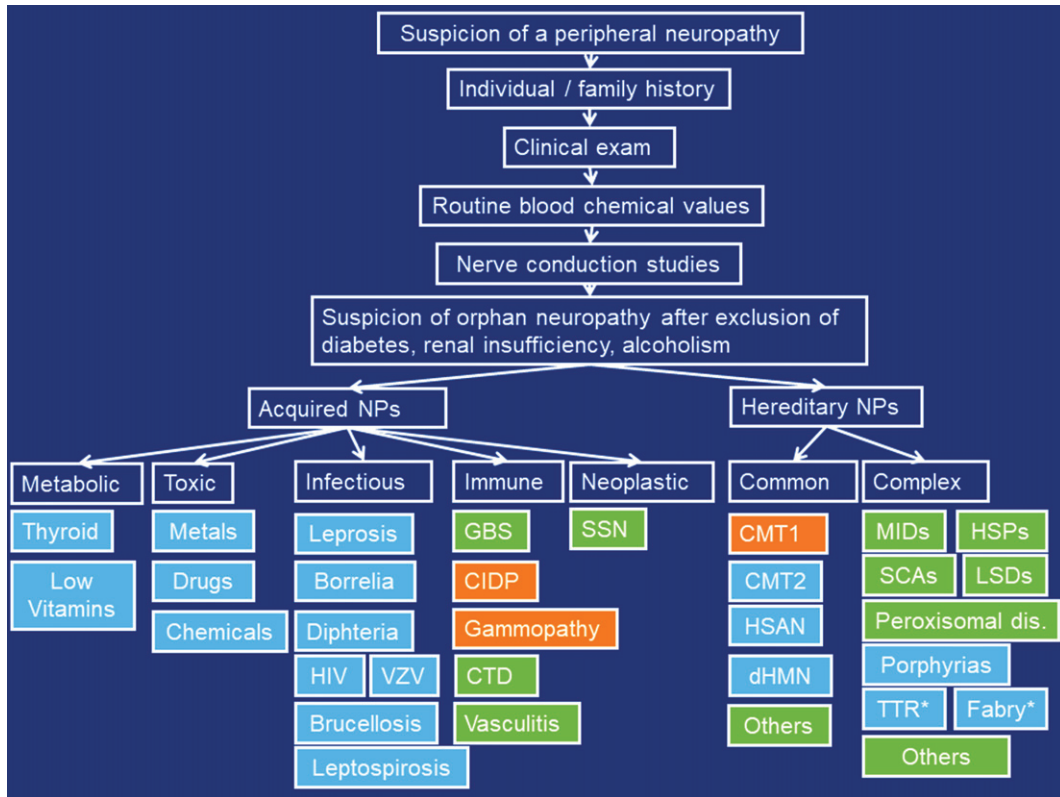


Fig. 2. Proposed diagnostic work-up for orphan peripheral neuropathies. Orange: demyelinating, blue: axonal, green: mixed. CTD: connective tissue diseases, SSN: subacute sensory neuropathy, MIDs: mitochondrial disorders, HSPs: hereditary spastic paraplegias, SCAs: spinocerebellar ataxias, LSDs: lysosomal storage diseases, TTR: transthyretin-related neuropathy, *: Treatable.

Metabolic neuropathies

Generally, metabolic neuropathies include diabetic, uremic, endocrine, and nutritive neuropathies. Particularly, among the nutritive neuropathies rare forms are known. Nutritive neuropathies are most frequently length-dependent, sensory neuropathies with the exception of vitamin-B12 deficiency neuropathy [11]. While diabetic and uremic neuropathies are highly prevalent, most of the other metabolic neuropathies are rare.

Endocrine

Hypothyroidism: Though hypothyroidism is a frequent abnormality worldwide, neuropathy attributable to hypothyroidism is extremely rare. The reason is that hypothyroidism is well-controlled in the majority of the cases, why the prevalence of neuropathy has declined. Onset of hypothyroid neuropathy is usually in early adulthood. Neuropathy due to hypothyroidism usually starts as SFN and may affect large fibers with progression of

the disease [12]. Patients initially complain about paresthesias and numbness of the feet. Hypothyroid neuropathy may manifest as mononeuropathy in the form of a carpal tunnel syndrome. NCSs reveal a length-dependent, sensory-motor axonopathy [13]. Hypothyroid neuropathy can be complicated by myopathy, which is more frequent than neuropathy.

Hyperthyroidism: Hyperthyroidism as a cause of neuropathy is extremely rare and debated. The clinical presentation can be similar to that of hypothyroidism but may also show up as a Guillain-Barre syndrome (GBS)-like presentation [14]. NCSs reveal a symmetric, sensori-motor, mixed, neuropathy with active denervation in lower extremity muscles. More frequent than neuropathy is myopathy due to hypothyroidism.

Vitamin deficiencies

Though vitamin deficiencies are frequently detected in the general population, neuropathy due to vitamin deficiency, with/without involvement of other systems, has been only rarely reported.

Low vitamin levels may be due to dietary causes (malnutrition, malabsorption, diarrhea), autoimmune conditions (e.g. perniciousa), certain drugs, alcoholism, chronic colitis, bariatric surgery, or due to other gastrointestinal compromise. Low vitamins that can go along with neuropathy include vitamin-B12, folic acid, thiamine (vitamin-B1), vitamin-B6, and vitamin-E. Why only a small portion of patients with vitamin deficiency develops neuropathy, remains speculative but one hypothesis is that pre-existing nerve pathology may be necessary for the development of a vitamin-deficiency-related neuropathy.

Vitamin-B12: Vitamin-B12-deficiency may be associated with distal, symmetric PNP and mainly, as in funicular myelosis, proprioceptive dysfunction. About 4% of the distal symmetric PNP are caused by vitamin-B12-deficiency [15]. Normal blood levels of vitamin-B12 do not exclude a clinically relevant, relative vitamin-B12-deficiency [16]. In such cases, increased methyl-malonate and homocysteine levels can support the diagnosis of relative vitamin-B12-deficiency [16]. However, methyl-malonate and homocysteine can be also increased in hypothyroidism, renal insufficiency, hypovolemia, vitamin-B6 deficiency, or in patients with heterozygous homocysteinemia [16, 17]. Contrary to other nutrition neuropathies, vitamin-B12-deficiency manifests with a length-independent, sensory neuropathy [11]. Patients with vitamin-B12-deficiency usually present with concomitant myelopathy [11].

Folic acid: PNP due to folate deficiency is rare and manifests with slowly progressive distal symmetric, sensory neuropathy [18]. Folate-deficient neuropathy predominantly affects the lower limbs. Cognitive and affective symptoms of folate-deficiency are far more common than PNP and the laboratory test for folate-levels is only relevant in this clinical context [19]. Since folate deficiency causes secondary thiamine deficiency, neuropathy in folate deficiency can be blended by thiamine deficiency neuropathy [20].

Thiamine: Not only central nervous system (CNS) symptoms occur with thiamin-deficiency (Wernicke encephalopathy, Marchiafava-Bignami, dry beriberi), but also distal axonal, sensory-motor, length-dependent PNP has been described. Thiamine deficiency-related PNP is often painful and has been described in the context of bariatric surgery or severe alcohol-abuse [21].

Vitamin-B6: Vitamin-B6 deficiency almost exclusively develops in the context of drugs that reduce vitamin-B6 resorption (e.g. isoniazid) [22] and cause axonal distal sensory-motor PNP. A further

cause of vitamin-B6 deficiency can be chronic dialysis [23].

Vitamin-E: Vitamin-E deficiency may cause a distal symmetric PNP with severe, sensory ataxia. Since vitamin-E deficiency is frequently associated with a spinocerebellar syndrome, concomitant cerebellar ataxia may occur [11, 24]. However, vitamin-E deficiency is a rare cause of PNP and serum levels of vitamin-E should be determined only in patients with expected vitamin-E deficiency.

Toxic neuropathies

Metals

Metal intoxications most frequently not only cause isolated neuropathy but also systemic manifestations. Thus, systemic features should be considered in the diagnostic work-up of suspected metal intoxications.

Copper: Generally, copper deficiency (hypocupremia) manifests with bone marrow dysplasia, myelopathy, and neuropathy [25]. Neuropathy due to hypocupremia is rare and predominantly occurs after bariatric surgery, gastrectomy, or due to alcoholism [26]. Neuropathy is progressive, ascending and associated with gait ataxia, cerebellar ataxia, fatigue, dyspnea, macrocytic anemia, neutropenia, and unintentional weight loss. Neuropathy due to copper deficiency is usually sensory and symmetric. The clinical presentation is similar to that of funicular myelosis. Diagnostic is hypocupremia and low copper in the bone marrow biopsy. Serum copper should be particularly determined in patients with a funicular myelosis presentation but normal folic acid and cobalamin levels [13].

Lithium: Lithium has long been used in psychiatry as an adjuvant therapy for bipolar disorders. Occasionally, long-term treatment with lithium results in chronic intoxication, clinically manifesting as nystagmus, ataxia, tremor, memory impairment, myoclonus with generalised triphasic epileptiform discharges, dysarthria, fasciculations, clonus, and PNP [27]. PNP is usually a length-dependent, sensorimotor axonopathy. Frequently, lithium neuropathy shows a rapidly progressive course [28]. Patients under lithium therapy with symptoms and signs of PNP require quantification of the lithium serum level, NCSs, and eventually replacement of the causative agent. Discontinuation of lithium is usually followed by improvement or resolution of the PNP [13].

Lead: Lead intoxication most frequently results from industrial exposure and can cause a progressive, mostly asymmetric motor PNP that affects the upper

extremities more than the lower extremities. Classical lead neuropathy manifests with weakness of the wrist and finger extensors [29]. Lead intoxication often also causes anemia, gingival, dental, and cerebral changes (lead encephalopathy). The most well-known gingival abnormality is Burton's line [30]. The prognosis of recovery is favorable as long as exposure is terminated promptly [29].

Arsenic: The causes of arsenic intoxication are poisoning with contaminated water, ingestion of traditional medicine for obesity, or attempted homicide. Neuropathy is one among other manifestations of arsenic intoxication and presents as subacute, progressive, painful, sensory-motor neuropathy with autonomic dysfunction [31]. In some cases, neuropathy can be the only manifestation of the intoxication [31].

Thallium: Thallium intoxication has been reported in cases with accidental ingestion, suicide attempt, or criminal adulteration. Thallium intoxication may cause a progressive painful, sensory-motor PNP with autonomic dysfunction. In addition to neuropathy patients may develop visual loss, myalgia, leg weakness, acute gastrointestinal symptoms, or alopecia [13].

Mercury: Mercury intoxication causes an axonal, sensory PNP with small-fiber involvement and autonomic dysfunction [19, 32]. In addition to neuropathy, patients with mercury intoxication may present with diffuse full-body rash, fever, myalgias, headache, oral paresthesias, and tender cervical posterior lymphadenopathy.

Cobalt: Cobalt toxicity usually results from failed total hip replacement. Cobalt metallosis is rare but can be devastating [33]. Clinical manifestations of cobalt toxicity include cardiomyopathy, hypothyroidism, skin rash, visual and hearing impairment, polycythemia, muscle weakness, fatigue, cognitive impairment, and neuropathy [33]. Neuropathy is a progressive, length-dependent, sensory axonopathy with normal motor function [13].

Drugs

Neuropathy can be a side effect of several drug intoxications. Most well-known for their neuropathic toxicity are chemotherapeutics and nucleoside analogs. However, neuropathy may be also a side effect of non-chemotherapeutic drugs.

Non-chemotherapeutic drugs: Among the non-chemotherapeutic drugs neuropathy is most frequently caused by phenytoin, disulfiram, fluoroquinolones, linezolid, metronidazole, chloroquine,

dapsone, isoniazide, ethambutol, nitrofurantoin, nucleoside-analogs (dideoxycytidine, zalcitabine, dideoxiinosine, stavudine, lamivudine, thalidomide, tacrolimus, leflunomide, amiodarone, or colchicine). Rarely, toxic neuropathy occurs in association with vitamin-B6, L-DOPA, or statin overdose [34].

Vitamin-B6: Vitamin-B6 is the only vitamin that may cause PNP in the context of increased blood levels, which is mostly due to excess vitamin supplementation. Vitamin-B6 levels need to be elevated 50–100 times the upper level of normal to induce neuropathy. Vitamin-B6 toxicity causes a non-length dependent, sensory PNP with marked ataxia or a painful SFN [11, 35].

L-DOPA: Neuropathy due to L-DOPA is a length-dependent, sensory axonopathy, possibly related to elevated homocysteine or neuronal deposition of α -synuclein. In a study of 73 Parkinson patients without a history of previous PNP, 67.3% of those taking L-DOPA developed a PNP, whereas in the non-L-DOPA group only one patient developed PNP [36]. The results imply that long-term L-DOPA intake can secondarily cause vitamin-B12 and folate deficiency and consecutively PNP [36, 37].

Chemotherapeutics: Chemotherapy-induced peripheral neuropathy (CIPN) is a frequent complication of various chemotherapeutics. Most frequently neuropathy has been described in association with taxanes, vinca-alkaloids, platanes, and bortezomib. However, there are chemotherapeutics, such as the immune checkpoint inhibitors or eribulin, which have been only rarely described to be complicated by neuropathy. Immune checkpoint inhibitors (e.g. pembrolizumab, nivolumab, ipilimumab) are a new class of chemotherapeutic drugs being effective with refractory cancers [13]. Peripheral nervous system (PNS) side effects are rare and occur in <1% of the patients. PNS adverse events include symmetric, distal, axonal PNP, GBS, CIDP, and radiculitis [13]. Neuropathy occurs within 2–3 weeks after initiation of treatment. Neuropathy can be severe but resolves upon discontinuation of the drugs, and treatment with steroids, IVIG, or plasmapheresis [13]. Eribulin is a chemotherapeutic agent used to treat acute lymphatic leukaemia, myeloma, and metastatic breast cancer [38]. The most frequent non-hematological side effect of eribulin is an axonal, length-dependent, sensory PNP of mild to moderate severity [38]. Neuropathy resolves after discontinuation of the compound. Vinca-alkaloids, platins, taxanes, and thalidomide are more neurotoxic than eribulin. The initial manifestation of a CIPN may be SFN [39].

Chemicals and plants

A number of chemicals (e.g. nitric oxide, vinyl-benzene, di-ethylene-glycol, hexa-carbon, acrylamide, carbon-disulfide, and many others), is toxic to peripheral nerves [13]. Neuropathy due to intoxication with any of these molecules has been only rarely described. For example, acryl-amide causes, in addition to encephalopathy, dermatitis, and hyperhidrosis, a sensori-motor axonopathy [13]. Acryl-amide is neurotoxic as it directly attacks DNA or is transformed into glycidamid by liver enzymes [40]. Acrylamid and glycidamide bind to aminoacids and nucleotides and thus directly impair DNA functions. Hexa-carbon causes a subacute, length-dependent, sensori-motor axonopathy with secondary demyelination [13]. A length-dependent, sensori-motor axonopathy is also caused by carbon-disulfide. Diethylene-glycol causes an acute, rapidly progressive, sensori-motor axonopathy with demyelination [13]. Toxicity of vinyl-benzene manifests as painful, sensory, length-dependent SFN [13]. An example of a plant causing neuropathy is the buckthorn fruit, which occurs in south-west US and Mexico. Buckthorn causes a rapidly progressive, length-dependent, sensori-motor axonopathy with secondary demyelination [13]. The neuro-toxic agent in Buckthorn intoxication has been identified as T-544 [13].

Infectious neuropathies

The prevalence of infectious neuropathies is quite variable and strongly depends on the region of investigation [41]. What may be rare in one region, country, or continent, may be highly prevalent in another country. The prevalence of infectious neuropathies may also increase in association with epidemic outbreaks. Infectious agents most frequently causing neuropathy include *M. Leprae* (South America, Asia, Africa), *Borrelia burgdorferi* (Europe, America), *C. diphtheriae* (Asia), HIV (worldwide), VZV (worldwide), hepatitis-C (worldwide), HTLV1 (worldwide), Zika (GBS) (South America), influenza-A (GBS) (Europe), CMV (Europe, America), dengue (GBS) (Asia, Africa), Toscana-virus (Europe, Africa), and other arboviruses.

Immune-mediated neuropathies

Guillain Barre syndrome

The term GBS includes a group of autoimmune disorders that share a common presentation of acute/subacute, progressive poly-radiculo-

neuropathy [42]. The incidence of GBS varies between regions and countries from 1.1–1.8/100000/y to 2.66/100000/y [42]. There are several subtypes of GBS classified according to the underlying pathology, clinical presentation, and NCS features [42]. The most common subtype in Europe is acute, inflammatory, demyelinating poly-radiculo-neuropathy (AIDP) with primarily demyelinating features and a favourable prognosis [42]. Less common is acute, axonal, motor neuropathy (AMAN) with primary axonal injury, pure motor involvement, and a worse prognosis [42]. AMAN is the most prevalent subtype in East Asia. A rare cause of dysimmune and acquired neuropathy is acute painful autoimmune neuropathy, an acute small fiber neuropathy resembling GBS [43]. Acute, motor, sensory, axonal neuropathy (AMSAN) shares a similar pathogenesis with AMAN with additional sensory involvement. Miller-Fisher syndrome (MFS), is characterised by ophthalmoparesis, areflexia, and ataxia. Bickerstaff encephalitis presents similarly to MFS but additionally with impaired consciousness due to brainstem involvement. Less common variants are the pharyngeal-cervico-brachial variant, associated with GQ1b and GD1a antibodies and pandysautonomia, associated with GT1a antibodies [42, 44]. GBS is often preceded by an infection with *Campylobacter jejunii*, *mycoplasma pneumoniae*, EBV, CMV, influenza-A, or hepatitis-E [42, 45]. Micro-organisms more rarely triggering GBS include scrub typhus (Tsutsugamishi fever) [46], Chikungunya [47], rubella virus [45], VZV, Toscana virus, hepatitis-C, hepatitis-A, hepatitis-B, West Nile, COVID-19, SARS-CoV-2, or Zika [48]. Rare, non-infectious triggers of GBS include hyponatremia [49], bariatric surgery [50], lupus, pregnancy [42], or bacterial meningitis [51]. Antibodies associated with GBS include GM1/GD1a (AIDP), GM1/GT1a/GD1a (AMAN), or GD1a/GQ1b (AMSAN) [42].

CIDP

CIDP is a chronic, demyelinating, poly-radiculo-neuropathy, which manifests clinically with symmetric weakness and sensory disturbances. CIDP is diagnosed according to the EFNS/AAN/INCAT criteria if there is progressive or recurrent symmetric weakness of proximal and distal upper and lower extremities for at least 2 months. Frequently, there is dissociation cytoalbuminique and there is demyelination on NCSs (reduced or normal motor conduction velocity, conduction block, temporal dispersion, increased F-wave latency, prolongation of

distal latency and of the CMAP duration) [52]. According to these findings definite, probable, and possible CIDP are delineated. Several rare variants have been identified since the original description, including multifocal acquired demyelinating sensory and motor (Lewis-Sumner syndrome, MADSAM) neuropathy, a pure sensory form, distal, acquired, demyelinating, symmetric CIDP (DADS) neuropathy, and syndromes associated with monoclonal gammopathy [44]. Rarely, nerves innervating respiratory muscles or involvement of the autonomic nerves (bowel or bladder dysfunction, dry mouth/eyes, orthostatic intolerance, sexual dysfunction, flushing, hyperhidrosis) have been described [52]. In 2–6% of the cases CIDP is associated with elevated titers of auto-antibodies against the paranodal protein contactin-1 (CNTN-1), neurofascin-155 (NF-155), or contactin-associated protein-1 (Caspr1) [52]. These patients more frequently present with an acute onset, tremor and ataxia than CIDP patients without these antibodies and often poorly respond to standard immunotherapy [52]. Anti-CNTN-1 antibodies have been shown to interfere with the structural integrity of the paranodal region and are known to induce conduction block [53]. Occasionally, antibodies against gangliosides or MAG, are elevated in CIDP [44]. Most frequently these antibodies are found in patients with multifocal motor neuropathy (MMN) (GM1), DADS (anti-MAG), or chronic ataxic neuropathy with ophthalmoplegia, M-proteins, cold agglutinins and disialosyl antibodies (CANOMAD). The other parameters lack sufficient sensitivity and specificity to be used as reliable biomarkers. First-line treatment of CIDP includes steroids, intravenous immunoglobulins, and plasmapheresis.

Neuropathies related to monoclonal gammopathies (paraproteinemias)

Monoclonal gammopathies are a heterogeneous group of lymphoproliferative disorders characterised by overproduction and deposition of paraproteins (light chains, immunoglobulins). Monoclonal gammopathies include monoclonal gammopathy of unknown significance (MGUS), multiple myeloma, amyloidosis, Waldenström macroglobulinemia, and CANOMAD, polyneuropathy, organomegaly, endocrinopathy, monoclonal protein, and skin changes (POEMS) syndrome [13]. Neuropathy is a common manifestation in monoclonal gammopathies and attributed to a cross-reaction of the paraprotein with neural antigens, deposition of paraproteins in nerve or myelin, or due to a neurotoxic effect of the

paraprotein [13]. Other pathomechanisms include vasculitis due to cryoglobulinemia or infiltration of the nerve roots by a lymphoma. Neuropathy is particularly common in IgM-MGUS, multiple myeloma, and amyloidosis. More rarely, neuropathy develops in the remaining four types.

Waldenström's macroglobulinemia: Waldenström's macroglobulinemia is a rare subtype of B-cell lymphoma with elevated monoclonal IgM and clinically characterised by hyperviscosity syndrome, swelling of lymph nodes, cold agglutinin disease, anemia, thrombocytopenia, elevated IgM, amyloidosis, splenomegaly, Bing-Neel syndrome (infiltration of the CNS with malignant B-lymphocytes), and neuropathy [54]. Neuropathy in Waldenström's macroglobulinemia occurs in one fifth to one third of the patients [54]. Neuropathy is usually a chronic, progressive, symmetric, predominantly distal PNP [55]. NCSs show demyelinating features. Anti-MAG antibodies are elevated in about 50% of cases. Treatment relies on rituximab in combination with cyclophosphamide, hydroxy-doxorubicin, vincristine, and prednisone (R-, therapy) [54]. Treatment with drugs that induce toxic neuropathy such as vincristine, should be avoided. R-CHOP therapy is recommended but the use of vincristine may worsen neuropathy. Treatment should be discussed with hematologists in terms of risk benefit.

POEMS syndrome: POEMS syndrome is a rare paraneoplastic (lymphoma, Castleman syndrome, myeloma, plasmocytoma) condition, characterised by PNP, organomegaly due to elevation of serum vascular endothelial growth factor (VEGF), endocrinopathy, M-gradient λ -light chains derived from the germlines IGLV1–40 and IGLV1–44, extravascular volume overload, and skin changes [56]. Two thirds experience clonal plasma cell bone marrow infiltration and one third develops a plasmocytoma. Neuropathy in POEMS syndrome is severe, distal, sensory-motor, and predominantly of the demyelinating type [57]. Treatment is directed towards targeting monoclonal plasma cells with thalidomide or autologous stem cell transplantation (ASCT) [56]. Additionally, melphalan and dexamethason or lenalidomide and dexamethason can be beneficial. If myeloma is of the osteosclerotic type radiation therapy can be beneficial. Whether these types of treatment are also effective for neuropathy is unknown but conceivable.

CANOMAD: CANOMAD is an ultra-rare paraproteinemia, clinically manifesting with chronic ataxic neuropathy and ophthalmoparesis leading to gait

disturbance. In some patients cranial nerves may be additionally affected [58]. NCSs may show a mixed axonal/demyelinating pattern, pure axonal lesions, or rarely pure demyelinating lesions [59]. Ultrasound may show nerve enlargement patterns as in acquired demyelination [59]. Antibodies against GD1b and other disialosyl anti-ganglioside antibodies can be elevated [52]. Cold agglutinins may be positive. Patients with CANOMAD may respond favourably to intravenous immunoglobulins [60] or rituximab [61]. Autopsy in these patients may reveal dorsal column atrophy and dorsal root ganglionopathy, and infiltration of clonal B-lymphocytes within the endoneurium, perineurium, and leptomeninges [62].

Connective tissue disorders

Connective tissue disorders are multisystem, autoimmune disorders that show common features of organ inflammation (most commonly joints and skin) [13]. In many of the connective tissue disorders the CNS or PNS are involved. Neuropathy has been most frequently reported in lupus erythematosus and rheumatoid arthritis (75% of patients). Rarely, neuropathy occurs in sarcoidosis, Sjögren syndrome, or systemic sclerosis (scleroderma). Neuropathy in sarcoidosis frequently starts as SFN with prominent pain, areas of tenderness, numbness, and dysesthesias, responding only to immunoglobulins or TNF-alpha blockers [13]. LFN is much less common and manifests as length-independent PNP or polyradiculopathy, or rarely as mononeuritis multiplex, GBS (AIDP), symmetric sensori-motor neuropathy, or as pure sensory neuropathy [13]. Neuropathy in Sjögren's syndrome is usually a sensory, length-dependent PNP. Occasionally, sensory symptoms are patchy and asymmetric, suggesting ganglionopathy [13]. More rarely, neuropathy is sensori-motor taking a subacute or chronic course. Rarely, neuropathy presents as polyradiculopathy, mononeuritis multiplex, or autonomic neuropathy [13]. Neuropathy in systemic sclerosis (scleroderma) manifests as length-independent numbness and paresthesias of hands and feet [13].

Vasculitis

Vasculitic neuropathies result from non-infectious inflammation of the vasa nervorum [63]. Vasculitic neuropathy may occur in the context of systemic inflammation or from vasculitis confined to the peripheral nerves (non-systemic vasculitic neuropathy (NSVN)) [63]. Vasculitis may be primary (arteritis originates from the arteries) or secondary

(due to conditions such as connective tissue diseases, infections, paraneoplastic, immune-mediated conditions, or drug-induced) [63]. Vasculitic neuropathy typically presents with an acute or subacute onset of multiple, painful, sensory, or sensori-motor mononeuropathies [63]. All sensory modalities are affected as pure SFNs are rarely vasculitic [63].

Primary vasculitis

Systemic vasculitis: Systemic vasculitis manifesting with neuropathy includes panarteriitis nodosa, microscopic polyangiitis, eosinophilic granulomatosis with polyangitis (EGPA, formerly Churg-Strauss), granulomatosis with polyangitis (formerly Wegener granulomatosis), Hennoch-Schönlein purpura, giant cell arteritis, and essential mixed cryoglobulinemia [63]. The prevalence of vasculitic neuropathy is 65% in EGPA (Churg-Strauss), 23% in microscopic polyangiitis, and 19% in granulomatosis with polyangiitis (Wegener) [64]. c-ANCA and p-ANCA may be positive in Wegener granulomatosis and Churg-Strauss syndrome.

Non-systemic vasculitic neuropathy (NSVN): NSVN is a single-organ vasculitis of the peripheral nerves that can be diagnosed only by nerve biopsy [65]. Subtypes of NSVN include Wartenberg migratory sensory neuropathy (Wartenberg syndrome), non-diabetic, lumbosacral, radiculo-plexus neuropathy, postsurgical inflammatory neuropathy, and Parsonage-Turner syndrome (neuralgic amyotrophy) [65]. Cutaneous polyarteritis nodosa and other skin-nerve vasculitides overlap with NSVN. Clinically, three patterns of involvement are delineated, multifocal neuropathy, distal symmetric PNP, and asymmetric PNP [65]. NSVN and neuropathy-predominant systemic vasculitis respond more favourably to steroids plus an immunosuppressant than to steroids alone [65]. After treatment, NSVN rarely spreads to other organs but one third of the patients experience relapses [65]. Long-term outcome is favourable but chronic pain is common [65].

Secondary vasculitis: Secondary vasculitis may be due to conditions such as metabolic disease, connective tissue diseases, infections, paraneoplastic conditions, immune-mediated conditions, or drug-induced. An example of non-systemic, secondary vasculitis of the PNS is Bruns-Garland syndrome (BGS), also known as diabetic amyotrophy. BGS is a rare proximal neuropathy clinically characterised by sudden onset asymmetric proximal pain and weakness [66, 67]. BGS presents with stepwise or rapid progression within 2 to 18 months [67]. The con-

tralateral extremity becomes involved within 3d to 8 months with affection of proximal and distal muscles [67]. Neuropathy in BGS is of the axonal type. Sural nerve biopsy shows multifocal variability of nerve fiber density with non-random fiber loss [67].

Neoplastic

Neuropathies due to neoplasms are rare but have been occasionally reported as acute, demyelinating neuropathy in neurolymphomatosis due to direct infiltration of the PNS [68], as upper limb neuropathies in epithelioid hemangio-endothelioma (EHE) [69], as infiltration of the plexus by lung cancer (Pancoast) [70], as plexopathy in breast cancer, or as peripheral nerve metastasis [71].

Paraneoplastic

Paraneoplastic neuropathies are regarded as a secondary complication of a primary neoplasm due to reaction of the immune system against the neoplasm. Paraneoplastic neuropathies develop prior or after detection of a malignoma and are attributed to a remote effect of the malignoma, irrespective of neoplastic infiltration, chemotherapy, infection, or metabolic complications [72–74]. Paraneoplastic neuropathies occur in <1% of patients with malignoma [72]. Definite and possible paraneoplastic neuropathies are delineated [72]. Definite paraneoplastic neuropathies include those with a direct link between malignoma and neuropathy in the presence of an antibody, those representing a well-established paraneoplastic syndrome but without an identified antibody, and those which improve upon successful treatment of malignancy [72]. With regard to the antigen localisation, two types of antigens are delineated, intracellular and membrane-bound antigens [72]. The most frequent intracellular antigens are HuD and CRMP5. The most frequent membrane bound antigen is Caspr2 [72].

Paraneoplastic neuropathies are classified as neuropathies (subacute sensory neuropathy (SSN (Denny Brown syndrome), lower motor neuron disease, sensory-motor neuropathy, autonomic neuropathy), as sensorimotor neuropathies without gammopathy (axonal, mixed axonal/demyelinating, demyelinating, vasculitic), as sensorimotor neuropathies with gammopathy (axonal, sensory and painful (AL-amyloidosis, myeloma), demyelinating (Waldenström, non-Hodgkin lymphoma), POEMS, vasculitic), and as neuromyotonia. An estimation of

the number of these subtypes so far reported is provided by Antoine et al. 2017 [72].

The most common of the paraneoplastic neuropathies is SSN [72]. It is probably T-cell mediated and targets neurons in dorsal root ganglia [72]. Sensory disturbances are multifocal, asymmetric, involve the upper limbs in a length-independent manner, and progress rapidly over weeks [72]. NCSs show reduced or absent sensory nerve action potentials. SSN is associated with small cell lung cancer (SCLC) in 70–80% of cases [75]. Most patients have anti-Hu antibodies, some CRMP5 antibodies, and in 10% no antibodies are found. Among the sensory-motor neuropathies without gammopathy the mixed axonal/demyelinating subtype is the most frequent and associated with CRMP5 antibodies. Among those with CRMP5 antibodies about 50% develop neuropathy. Only anecdotally anti-Yo, or anti-Ma2 antibodies have been reported.

Acquired neuro-myotonia (peripheral nerve hyperexcitability), clinically characterised by cramps, stiffness, twitching, spasms, weakness, paresthesias, hyperhidrosis, and abnormal relaxation, occurs most frequently in association with thymoma, SCLC, or lymphoma. Frequently, Caspr2 antibodies and rarely netrin-1 antibodies can be found.

Pure sensory neuropathies

Pure sensory neuropathies (PSNs) are usually acquired but can be also hereditary. A subtype of acquired PSN is sensory neuropathy with anti-FGFR3-autoantibodies. PSN can be also associated with vitamin-B12 deficiency. Chronic immune sensory polyradiculopathy (CISP) is a pure sensory form of CIDP. There are pure sensory forms of LFNs associated with connective tissue disorders. PSN may be a manifestation of NSVN. Among the mononeuritis multiplex neuropathies, a pure sensory form with IgG1 deficiency has been reported. As a counterpart to MMN, multifocal sensory demyelinating neuropathy has been described. Statins are known to cause a pure sensory and autonomic ganglionopathy. Pure sensory GBS is a rare entity.

HEREDITARY NEUROPATHIES

Hereditary neuropathies can be common or complex (Tables 1 and 2). Common hereditary neuropathies are characterised by isolated or predominant affection of the peripheral nerves, whereas complex hereditary neuropathies are characterised

Table 1
Overview about hereditary neuropathies (updated until 31st August 2020)

Gene	Disease	Phenotype	Frequency	Therapy
CMT/HMSN				
CMT1 (AD, demyelinating)				
PMP22	CMT1A (dupl/del)	Classical CMT1, DSD, CHN	~40% of CMTs	symptomatic
MPZ	CMT1B	CMT1, DSD, CHN, CMT2	~3% of CMT	symptomatic
LITAF	CMT1C	CMT1	<1% of CMT	symptomatic
EGR2	CMT1D	CMT1, DSD, CHN	<1% of CMT	symptomatic
PMP22 (exon 4)	CMT1E	CMT1	<1% of CMT	symptomatic
NEFL	CMT1F	CMT1, CMT2	<1% of CMT	symptomatic
FBLN5	CMT1H	HMN, macula degeneration	<1% of CMT	symptomatic
ARHGEF10	CMT1	asymptomatic	<1% of CMT	none required
CMT2 (AD, axonal)				
MFN2	CMT2A	CMT2, optic atrophy	~3% of CMT	symptomatic
RAB7	CMT2B	CMT2, mutilating ulcers	<1% of CMT	symptomatic
TRPV4	CMT2C	CMT2, vocal cord	<1% of CMT	symptomatic
GARS	CMT2D	CMT2	<1% of CMT	symptomatic
NEFL	CMT2E	CMT2	<1% of CMT	symptomatic
HSPB1	CMT2F	CMT2	<1% of CMT	symptomatic
MPZ	CMT2I	CMT2, late onset	<1% of CMT	symptomatic
MPZ	CMT2J	CMT2, hypoacusis,	<1% of CMT	symptomatic
GDAP1	CMT2K	CMT2, late onset	<1% of CMT	symptomatic
HSPB8	CMT2L	CMT2	<1% of CMT	symptomatic
DNM2	CMT2M	CMT2, im CMT, cataract, ptosis	<1% of CMT	symptomatic
AARS	CMT2N	CMT2	<1% of CMT	symptomatic
LRSAM1	CMT2P	CMT2	<1% of CMT	symptomatic
DHTKD1	CMT2Q	CMT2	<1% of CMT	symptomatic
MME	CMT2T	CMT2	<1% of CMT	symptomatic
MARS	CMT2U	CMT2, congenital	<1% of CMT	symptomatic
TFG	CMT2	CMT2, proximal involvement	<1% of CMT	symptomatic
HARS	CMT2	CMT2	<1% of CMT	symptomatic
VCP	CMT2	CMT2	<1% of CMT	symptomatic
KIF5A	CMT2	CMT	<1% of CMT	symptomatic
JAG1	CMT2	CMT2	2 families	symptomatic
CMT2 (AR, axonal)				
LMNA	CMT2B	CMT2	<1% of CMT	symptomatic
TRIM2	CMT2R	CMT2	<1% of CMT	symptomatic
IGHMBP2	CMT2S	CMT2	<1% of CMT	symptomatic
HSJ1	CMT2	CMT2	<1% of CMT	symptomatic
CMT4 (AR, demyelinating)				
GDAP1	CMT4A	CMT2, vocal cord, diaphragm	<1% of CMT	symptomatic
MTMR2	CMT4B1	CMT1, facial, bulbar	<1% of CMT	symptomatic
SBF3	CMT4B2	CMT1, glaucoma	<1% of CMT	symptomatic
MTMR5	CMT4B3	CMT1	<1% of CMT	symptomatic
SH3TC2	CMT4C	CMT1, scoliosis	<1% of CMT	symptomatic
NDGR1	CMT4D	CMT1, hypoacusis, gypsy	<1% of CMT	symptomatic
EGR2	CMT4E	CMT1, DSD, CHN	<1% of CMT	symptomatic
PRX	CMT4F	CMT1, sensory dominant	<1% of CMT	symptomatic
HK1	CMT4G	CMT1, gypsy	<1% of CMT	symptomatic
FGD4	CMT4H	CMT1	<1% of CMT	symptomatic
FIG4	CMT4J	CMT1	<1% of CMT	symptomatic
CTDP1	CMT4	CMT1, cataract, gypsy	<1% of CMT	symptomatic
SURF1	CMT4	CMT1	<1% of CMT	symptomatic
CMT4 (X-linked)				
GJB1	CMTX1	CMT1 (males), CMT2 (females)	~3% of CMT	symptomatic
AIFM1	CMTX4	CMT2, hypoacusis, development ↓	<1% of CMT	symptomatic
PRPS1	CMTX5	CMT2, hypoacusis, optic atrophy	<1% of CMT	symptomatic
PDK3	CMTX6	CMT2	<1% of CMT	symptomatic
CMT intermediate (AD)				
DNM2	CMTDIB	intermediate CMT or CMT2	<1% of CMT	symptomatic
YARS	CMTDIC	intermediate CMT	<1% of CMT	symptomatic
MPZ	CMTDID	intermediate CMT	<1% of CMT	symptomatic
IFN2	CMTDIE	intermediate CMT, renal failure	<1% of CMT	symptomatic
GNB4	CMTDIF	intermediate CMT	<1% of CMT	symptomatic

(Continued)

Table 1
(Continued)

Gene	Disease	Phenotype	Frequency	Therapy
CMT intermediate (AR)				
GDAP1	CMTRIA	intermediate CMT	<1% of CMT	symptomatic
PLEKHG5	CMTRIC	intermediate CMT	<1% of CMT	symptomatic
COX6A1	CMTAID	intermediate CMT	<1% of CMT	symptomatic
SORD	CMTRI	intermediate CMT	<1% of CMT	symptomatic
HSN/HSAN				
HSN/HSAN (AD)				
SPTLC1	HSAN1A	HSN, mutilating ulcers	rare	symptomatic
SPTLC2	HSAN1C	HSN, mutilating ulcers	rare	symptomatic
RAB7	CMT2B	HSN, mutilating ulcers	rare	symptomatic
ATL1	HSN1D	HSN, mutilating ulcers	rare	symptomatic
DNMT1	HSN1E	HSN, hypoacusis, dementia	rare	symptomatic
ATL3	HSN1F	HSN, bone destruction	rare	symptomatic
SCN11A	HSAN7	insensitivity to pain	rare	symptomatic
PRNP	HSAN	HSN, dementia	rare	symptomatic
HSN/HSAN (AR)				
WNK1	HSAN2A	HSN, mutilating ulcers	rare	symptomatic
FAM134B	HSAN2B	HSN, mutilating ulcers	rare	symptomatic
KIF1A	HSAN2C	HSN, mutilating ulcers	rare	symptomatic
IKBKAP	HSAN3	HSN, absent papillae, Jewish	rare	symptomatic
SCN9A	HSAN	insensitivity to pain, SFN	rare	symptomatic
NTRK1	HSAN4	insensitivity to pain	rare	symptomatic
NGF-B	HSAN5	insensitivity to pain	rare	symptomatic
DST	HSAN6	HSN, absent papillae, Jewish	rare	symptomatic
CCT5	HSN	HSN, spastic paraplegia	rare	symptomatic
HMN				
HMN (AD)				
HSPB8	HMN2A	HMN	rare	symptomatic
HSPB1	HMN2B	HMN	rare	symptomatic
HSPB3	HMN2C	HMN	rare	symptomatic
FBXO38	HMN2D	HMN	rare	symptomatic
SETX	HMN	HMN, pyramidal signs	rare	symptomatic
GARS	HMN5A	hand wasting	rare	symptomatic
REEP1	HMN5B	hand wasting, pyramidal signs	rare	symptomatic
IGHMBP2	HMN6	respiratory muscles	rare	symptomatic
SLC5A7	HMN7A	HMN, vocal cord	rare	symptomatic
DCTN1	HMN7B	HMN, facial, bulbar	rare	symptomatic
DYNC1H1	SMALED	contractures, pyramidal signs	rare	symptomatic
BICD2	SMALED2	contractures, pyramidal signs	rare	symptomatic
TRPV4	PNMHH	MHN, scapular winging	rare	symptomatic
AAR5	HMN	HMN	rare	symptomatic
WARS	HMN	distal motor neuropathy	rare	symptomatic
HMN (AR)				
HINT1	HMN	HMN	rare	symptomatic
VRK1	HMN	distal motor neuropathy	rare	symptomatic
SORD	HMN	distal motor neuropathy, diabetes	rare	symptomatic
SIGMAR1	HMN	motor neuropathy, pyramidal signs	rare	symptomatic
HMN (XL)				
LAS1L	SMAX	respiratory muscles	rare	symptomatic
ATP7A	SMAX3	HMN	rare	symptomatic
Other				
GAN	GAN	NP, progressive, multisystem dis	rare	symptomatic
PMP22	HNPP	liability to pressure palsies	frequent	symptomatic
PMP22	plexopathy	painless plexopathy	rare	symptomatic
SEPT9	plexopathy	painless plexopathy	rare	symptomatic
TTR	SFN	sensory, not progressing to LFN	rare	tafamidis, patisiran
SPTLC2	SFN	sensory, not progressing to LFN	rare	symptomatic
POLG1	SFN	sensory, not progressing to LFN	rare	symptomatic
SCN9A	SFN	sensory, progressing to LFN	rare	symptomatic
SCN10A	SFN	sensory, progressing to LFN	rare	symptomatic
SCN11A	SFN	sensory, progressing to LFN	rare	symptomatic
COL6A5	SFN	sensory, progressing to LFN	rare	Symptomatic
SPTBN4	axonal neuropathy	motor, myopathy, hypoacusis	rare	Symptomatic

CHN: congenital hypomyelinating neuropathy, DSD: Dejerine-Sottas disease, HMN: hereditary motor neuropathy, im: intermediate, SFN: small fiber neuropathy, SMA: spinal muscular atrophy.

Table 2
Overview of orphan, complex hereditary neuropathies

Group	Disorder	Gene	Phenotype	Treatment	
MIDs	NARP	MT-ATP6	multisystem	symptomatic	
	MNGIE	TYMP2	multisystem	ERT	
	SCAE	POLG1	multisystem	symptomatic	
	SANDO	POLG1	multisystem	symptomatic	
	Non-syndromic	mtDNA, nDNA	multisystem	symptomatic	
HSPs	SPG1	L1CAM	paraspasticity, MASA syndrome	symptomatic	
	SPG2	PLP1	paraspasticity, dementia, optic atrophy	symptomatic	
	SPG3	ATL1	paraspasticity, Silver syndrome	symptomatic	
	SPG4	SPAST	paraspasticity, dementia, epilepsy	symptomatic	
	SPG5	CYP7B1	paraspasticity, leucoencephalopathy	symptomatic	
	SPG6	NIPA1	paraspasticity, epilepsy, dystonia	symptomatic	
	SPG7	SPG7	paraspasticity, optic/cerebellar atrophy	symptomatic	
	SPG9B	ALDH18A1	paraspasticity, cataract	symptomatic	
	SPG10	KIF5A	paraspasticity, Parkinsonism	symptomatic	
	SPG11	KIAA1840	paraspasticity, Parkinsonism, ataxia	symptomatic	
	SPG14	SPG14	paraspasticity, retardation	symptomatic	
	SPG15	ZFYVE26	paraspasticity, retardation, retinopathy	symptomatic	
	SPG25	SPG25	paraspasticity, disc herniation	symptomatic	
	SPG27	SPG27	paraspasticity, retardation	symptomatic	
	SPG30	KIF1A	paraspasticity, cerebellar signs	symptomatic	
	SPG31	REEP1	paraspasticity, Silver syndrome, ataxia	symptomatic	
	SPG36	SPG36	paraspasticity	symptomatic	
	SPG38	SPG38	paraspasticity, Silver syndrome	symptomatic	
	SPG39	NTE	paraspasticity, spinal cord atrophy	symptomatic	
	SPG43	C19orf12	paraspasticity, Silver syndrome	symptomatic	
	SPG47	AP4B1	paraspasticity, retardation	symptomatic	
	SPG49	TECPR2	paraspasticity	symptomatic	
	SPG55	C12orf65	paraspasticity	symptomatic	
	SPG56	CYP3U1	paraspasticity	symptomatic	
	SPG57	TFG	paraspasticity	symptomatic	
	SPG76	CAPN1	paraspasticity	symptomatic	
	SCAs	SCA1–37	nDNA genes	ataxia	symptomatic
LSDs	Schindler's disease	NAGA	regression, seizures, cardiomyopathy	symptomatic	
	Ohtahara syndrome	DMXL2	epilepsy, encephalopathy	symptomatic	
	Metachromatic leukodystrophy	ARSA	ataxia, spasticity, optic atrophy, dementia	symptomatic	
	Fabry disease	GLA	corneal, gastrointestinal, cerebral	agalsidase α , β	
	Beta-mannosidase	MANBA	behavioral change, hypoacusis, keratoma	symptomatic	
	Krabbe disease	GALC	seizures, cognitive decline	symptomatic	
	Sandhoff disease	HEXB	motor neuron disease	symptomatic	
	Gaucher disease	GBA	anemia, thrombopenia, hepatosplenomegaly	ERT	
	Nieman Pick type-C	NPC1, NPC2	hepatosplenomegaly, ophthalmoparesis	cyclodextrine	
	Galactosialidosis	CTSA	hepatosplenomegaly, edema, dysmorphism	symptomatic	
	Mucopolipidosis	MCOLN1	Sialidosis	symptomatic	
	Ceroid lipofuscinosis	nDNA	epilepsy, dementia	symptomatic	
	Pompe disease	GAA	cardiomyopathy, myopathy, aneurysm	ERT	
	PSDs	Zellweger syndrome	PEX1	encephalopathy, dysmorphism	symptomatic
		Adrenoleucodystrophy	ABCD1	encephalopathy, dementia, hypocorticism	symptomatic
		Refsum disease	PDXK	PNP	pyridoxal
	Porphyrias	DOSS porphyria	ALAD1	neuro-visceral attacks	givosiran
Acute intermittent porphyria		HMBS	abdominal pain, weakness, hallucinations	givosiran	
Hereditary coproporphyria		CPOX	abdominal pain, diarrhea, seizures	hemin	
Variegate porphyria		PPOX	gastrointestinal, seizures, hallucinations	liver transplantation	
Others	Transthyretin amyloidosis	TTR	cardiomyopathy, PNP	tafamidis, patisiran	
	Sensory neuropathy	RFC1	cerebellar ataxia, vestibular dysfunction	symptomatic	
	Tangier disease	ABCA1	yellow tonsils, hepatosplenomegaly	symptomatic	
	Braun-Vialetto-Van Laere syndrome	SLC52A2	riboflavin deficiency, ataxia, hypoacusis	riboflavin	
	Progressive myoclonus epilepsy	SCARB2	seizures	symptomatic	
	Hereditary neuropathy+diabetes	SORD	diabetes	symptomatic	
	Methyl-malonic aciduria	CB1C	hyperhomocysteinemia	hydroxy-cobalamin	
	MTHFR deficiency	MTHFR	diabetic neuropathy	folic acid	
	Neurodevelopmental disease	NARS1	microcephaly, seizures, ataxia, delay	symptomatic	
Waardenburg syndrome	SOX10	visual impairment, leukodystrophy	symptomatic		

ERT: enzyme replacement therapy, PNP: polyneuropathy, PSD: peroxisomal disorders.

by being part of a hereditary multisystem disorder, which overshadows neuropathy [10]. Generally, hereditary neuropathies are classified according to the 1) clinical manifestations (hereditary sensory-motor neuropathies (HMSN), hereditary sensory-autonomic neuropathies (HSAN), distal hereditary motor neuropathies (dHMN)), 2) nerve conduction studies (NCSs, axonal, demyelinating, mixed), 3) mode of inheritance (autosomal dominant (AD), autosomal recessive (AR), X-linked (XL), maternally transmitted), and 4) mutated gene. HMSN types are also known as Charcot-Marie-Tooth (CMT) disease. The most widely used classification system is the one proposed by Dyck et al. [1]. This classification system has been repeatedly revised and the current version also includes the mutated genes.

Common hereditary neuropathies

Among common hereditary neuropathies the frequency of rare forms is particularly high. A large number of common hereditary neuropathies has been reported only in a single family or a few families. [76]. Often the pathogenic variant has been detected only in one or a few family members. Rare hereditary neuropathies have been most frequently identified by panel investigations or whole exome sequencing (WES). Common hereditary neuropathies are classified as CMT/HMSN (~75% of common hereditary neuropathies), with predominant motor and sensory involvement, as HSAN (~3% of common hereditary neuropathies) with predominant sensory or autonomic involvement, or as distal hereditary motor neuropathy (HMN) (~3% of common hereditary neuropathies) [77]. There is a significant overlap between HMN, HMSN, and HSAN [10]. Other common hereditary neuropathies include hereditary neuropathy with liability to pressure palsies (HNPP) (~3% of hereditary neuropathies), hereditary plexopathy, giant axonal neuropathy (GAN), and the hereditary SFNs [77]. Several subtypes derive from inclusion of the underlying mutated gene in the classification. Currently, mutations in >170 genes have been identified as causes of hereditary neuropathies [76].

CMT (HMSN)

More than 120 genes have been identified, which are associated with the CMT/HMSN phenotype (Table 1) [78]. Genes most frequently mutated in CMT1 phenotypes (AD, demyelinating) are *PMP22* (duplication/deletion), *GJB1*, *MFN2*, and *MPZ* genes

with high variability between regions of investigation. According to a study from the UK, >90% of the CMTs are due to mutations in these four genes [10]. CMT2 (AD or AR, axonal), CMT4 (AR, demyelinating) phenotypes due to mutations in the remaining genes have to be regarded as orphan diseases. In a study of 245 CMT patients from Norway the prevalence of CMT/HMSN in the general population was 1 in 1214 [79]. Contrary to the UK study, the prevalence of the *PMP22* duplication, *GJB1* mutations, *MPZ*, and of *MFN2* mutations in the cohort was only 13.6% [79]. In a study of 612 patients with hereditary neuropathies the genetic defect was identified in 121 patients (19.8%) [80]. Of these, 54.4% showed an AD, 33.9% an AR, and 11.6% XL inheritance. The most frequently affected genes were *PMP22* (16.4%), *GJB1* (10.7%), *MPZ*, and *SH3TC2* (both 9.9%), and *MFN2* (8.3%) [80]. Overall, a genetic diagnosis can be reached in ~80% of the demyelinating CMT1s but only in ~25% of axonal CMTs. CMT2 due to mutations in *HINT1* may go along with neuromyotonia [81].

An example of a rare CMT is CMT4C which is due to mutations in *SH3TC2* [82]. CMT4C is the commonest of the AR transmitted, common hereditary neuropathies. Onset of CMT4C is in infancy. Usually, CMT4C is restricted to the peripheral nerves. In single cases, however, cerebellar involvement may occur. Scoliosis is a major feature. CMT4C patients do not manifest with cardiomyopathy, endocrine abnormalities, or increased iron accumulation in the dentate nuclei [82]. Neuropathy manifests clinically with generalised wasting, muscle hypotonia, pes cavus, and scoliosis. Neuropathy in these patients is of the demyelinating type and slowly progressive. Rarely, cerebellar signs and hypoacusis may be present [82].

HSAN

HSAN represent ~3% of hereditary neuropathies [77]. Currently, mutations in >25 genes are made responsible for the respective HSAN subtypes (Table 1) [76]. All HSANs have to be regarded as rare or ultra-rare diseases (Table 1).

Distal HMN

Distal HMNs are rare. Like the HSANs, HMNs constitute ~3% of the hereditary neuropathies [77]. Currently, mutations in >35 genes are made responsible for distal HMNs (Table 1) [76]. All of them have orphan status.

Other common hereditary neuropathies

These include HNPP, GAN, hereditary plexopathy, and the hereditary SFNs. With the exception of HNPP, which is due to duplications/deletions in *PMP22* these neuropathies are very rare.

Giant axonal neuropathy (GAN): GAN is a severe, pediatric, AR disorder caused by mutations in *GAN*, which encodes gigaxonin [83]. Gigaxonin is involved in protein degradation via the ubiquitin-proteasome system [10]. Onset of GAN is usually in childhood. Phenotypically, patients manifest with a progressive multisystem disorder including severe sensorimotor neuropathy, cerebellar ataxia, cranial nerve involvement, bulbar symptoms, intellectual disability, pes cavus, scoliosis, distinctive curly (kinky) hair, and ophthalmologic abnormalities [10, 83]. Usually, patients become wheelchair-bound in the second decade of life [83]. Neuropathologically, accumulation of intermediate filaments (IFs) can be found in neurons [84]. IFs show strong immune-histochemical positivity for glial fibrillary acidic protein (GFAP) [84]. IFs also occur in the lens [84].

Hereditary plexopathy: Hereditary plexopathy is rare although it may occur in the context of HNPP [85]. The most common cause of hereditary plexopathy is a deletion in *PMP22* [85]. Recurrent painless plexopathy may be the exclusive manifestation of HNPP [86]. Recently, mutations in *SEPT9* have been made responsible for hereditary neuralgic amyotrophy (HNA) [87]. Hereditary plexopathy due to mutations in *SEPT9* was first described in 2005 [88] and represents <10% of the hereditary plexopathies.

Hereditary small fiber neuropathies: Small fiber neuropathies (SFNs) are common [89]. The gold standard for diagnosing the condition is skin biopsy showing reduced intra-epidermal nerve fiber density [89]. SFN may affect only small fibers without progression to large fibers during the entire course, or may progress to large-fiber neuropathy (LFN) over time. The most well-known SFN progressing to LFN and the most frequent is the one associated with mutations in the *TTR* gene. SFN has been additionally reported in the early stages of HSAN1C due to mutations in *SPTLC2* [90]. SFNs may not only occur in association with common but also with complex hereditary neuropathies. SFN has been also reported in mitochondrial disorders (MIDs), particularly in MIDs due to *POLG1* mutations [91]. In a study of 27 genetically proven MID patients, 33% had a SFN as assessed by the sympathetic skin response (SSR) or the Sudoscan®, [91]. Hereditary SFNs, which do

not progress to LFN include SFNs due to mutations in *SCN11A*, *SCN9A*, *SCN10A*, and *COL6A5* [92].

Complex hereditary neuropathies

Complex hereditary neuropathies can be more easily diagnosed than common hereditary neuropathies as they go along with concomitant pathology in systems other than the peripheral nerves. Accordingly, not only the neurologist may be involved or the first being confronted with such a phenotype but many other specialities depending on the time point at which other organs/tissues/structure become affected. Since some of the manifestations may favourably respond to symptomatic treatment, it is crucial that the managing physician refers these patients to other responsible specialities. Complex hereditary neuropathies are most prevalent among MIDs, hereditary spastic paraplegias (HSPs), spinocerebellar ataxias (SCAs), lysosomal storage disorders (LSDs), porphyrias, and other rare genetic conditions (Table 2).

Mitochondrial neuropathies

Many of the syndromic and non-syndromic MIDs manifest with neuropathy. Neuropathy may dominate the phenotype or may be only a collateral feature. Particularly, among the non-syndromic MIDs, neuropathy can be the only manifestation, usually at onset of the MID. Generally, the prevalence of neuropathies in MIDs is high but compared with the general population mitochondrial neuropathies are rare. Mitochondrial neuropathies more frequently occur with nDNA than mDNA variants, while neuropathies are rare with single mtDNA deletions.

NARP: Neuropathy, ataxia, and retinitis pigmentosa (NARP) syndrome is a MID due to the variant m.8993T>G in *MT-ATP6* with heteroplasmy rates of 70–90% [93]. Onset of NARP is usually in early infancy. NARP is clinically characterised by neuropathy, ataxia in the absence of cerebellar atrophy, and retinitis pigmentosa [93]. Neuropathy in NARP is usually a dominant feature, of the axonal type, sensory-motor, and slowly progressive [94]. Nerve biopsy shows peculiar, nuclear accumulations in Schwann cells, clusters of concentrically arranged Schwann cells in myelinated axons, and degenerated mitochondria [93]. In addition to the classical features, some patients develop leukoencephalopathy, seizures, or psychomotor retardation.

MNGIE: Mitochondrial neuro-gastro-intestinal encephalopathy (MNGIE) is a rare (~100 cases

worldwide) AR, multisystem MID due to mutations in *TYMP1* [95]. *TYMP1* deficiency results in accumulation of the nucleosides thymidine (dThd) and deoxyuridine (dUrd) [95]. Onset of MNGIE is usually in adolescence. Phenotypic manifestations of MNGIE include ptosis, ophthalmoparesis, severe gastrointestinal dysmotility with consecutive cachexia, leukoencephalopathy, and progressive sensorimotor neuropathy [95]. NCSs usually demonstrate demyelinating PNP [95]. Whether gastrointestinal dysmotility is due to involvement of the autonomic fibers or due to primary affection of the smooth muscle cells is under debate. Whether hemodialysis, liver transplantation, allogenic hematopoietic stem cell transplantation (AHSCT), or treatment with erythrocyte encapsulated thymidine phosphorylase is effective also for neuropathy in MNGIE patients, is unknown but conceivable.

SANDO: Sensory ataxic neuropathy, dysarthria, and ophthalmoparesis (SANDO) syndrome is a rare multisystem MID due to mutations in *POLG1* [96]. Both, AR and AD transmission have been reported. Onset of SANDO is in adulthood [97]. Phenotypically, SANDO manifests with dysarthria, dysphagia, ophthalmoplegia, and progressive, sensory, ataxic neuropathy. Additionally, involvement of the heart (e.g. cardiac arrest), liver, brain (depression, anxiety), or the intestines develops [96]. Some patients may present with features of MNGIE [96]. Neuropathy may not only manifest with sensory disturbances and weakness but also with twitches and cramps, and progressive gait disturbance ultimately leading to impaired mobility and requirement of a wheel chair [96].

MEMSA (SCAE): Myoclonus epilepsy, myopathy, sensory ataxia (MEMSA) syndrome previously termed spinocerebellar ataxia with epilepsy (SCAE), is a rare MID due to mutations in *POLG1*. Onset of MEMSA is in early adulthood. MEMSA includes an overlapping spectrum of abnormalities, including myopathy, epilepsy, and ataxia, in the absence of ophthalmoplegia. It may occur with or without ragged-red fibers [98]. Neuropathy in MEMSA spectrum disorders is rare, sensory, of the axonal type, and progressive. Though *POLG1* mutations are frequent, MEMSA has been only rarely reported. MEMSA should be considered in patients with myoclonic epilepsy, mitochondrial myopathy sparing the extraocular muscles, and sensory neuropathy.

Other mitochondrial neuropathies: In addition to the syndromic MIDs, a high number of non-

syndromic MIDs manifests with neuropathy as a collateral feature [99]. In a study of 108 MID patients, mitochondrial neuropathy was diagnosed in 35% [100]. In a study of 109 MID patients, 45% had neuropathy [99]. In a study of 116 genetically proven MIDs neuropathy predicted the presence of a nuclear defect [101]. Axonal or sensory neuropathy may occur in MELAS and MERRF.

Hereditary spastic paraplegias (HSPs)

HSPs are rare genetic disorders, clinically manifesting with spasticity predominantly of the lower limbs and urinary dysfunction (pure HSPs) [102]. Some of the HSPs, however, may manifest with additional phenotypic features, including neuropathy (HSP-plus) [102]. Currently, 80 different types of HSPs are differentiated, which are classified according to their mode of inheritance as AD, AR, XL, or maternal transmission (MT). HSPs, which not only manifest with paraspasticity and bowel or bladder dysfunction, but also with neuropathy alone or with other manifestations (HSP-plus), include SPG1–7, SPG9–11, SPG14–15, SPG25, SPG27, SPG30–31, SPG36, SPG38–39, SPG43, SPG47, SPG49, SPG55–57, and SPG76 [102]. Except for SPG4, SPG3, SPG31 (most frequent of the AD forms) and SGG11 (most frequent of the AR forms), all other SPGs are regarded as rare.

Spinocerebellar ataxias (SCAs)

Currently (8/2020), 37 types of SCAs (SCA1–SCA37) are known. Some of the SCAs may occasionally go along with neuropathy. These include SCA1 (sensory neuropathy) [103], SCA2 (axonal neuropathy) [104], SCA3 (Machado-Joseph disease) [105], SCA4 [106], SCA6 [78], SCA7 [107], SCA10 [108], SCA11 [109], and SCA18 [110]. Neuropathy may be also a feature in non-classified SCAs, such as those due to mutations in *SETX* [111]. SCAs with neuropathy are generally rare.

Porphyrias

Porphyrias are a group of ultrarare, mostly hereditary metabolic disorders due to a defective heme biosynthesis pathway [112]. Primary (hereditary) and secondary (acquired) porphyrias are differentiated. Primary porphyrias are subdivided into hepatic and erythropoietic forms. Among the hepatic porphyrias, acute porphyrias (acute intermittent porphyria, variegate porphyria, coproporphyrinuria, DOSS porphyria (ALA-dehydratase (porphobilinogen synthase) deficiency), the most common of the porphyrias termed

after Dr. Doss) and chronic porphyrias (porphyria cutanea tarda, hepato-erythropoetic porphyria) are delineated. The phenotype depends on the defective enzyme within the pathway and is due to accumulation of intermediate metabolites. Neuro-visceral porphyrias are characterized by recurrent, acute attacks, triggered by excessive hem synthesis, clinically manifesting as severe abdominal pain, vomiting, tachycardia, hypertension, hyponatremia, mild cognitive impairment, and peripheral neuropathy [112]. Severe attacks may manifest with seizures, psychosis, quadriparesis, respiratory failure, coma, or death [112]. Neuropathy occurs particularly in aminolevulinic acid dehydratase (*ALAD1* gene) porphyria (DOSS porphyria), acute intermittent porphyria (*HMBS* gene), hereditary coproporphyrinuria (*CPOX* gene), and variegate porphyria (*PPOX* gene) [112]. Not only peripheral nerves but also cranial nerves can be affected. Neuropathy is usually axonal and develops rapidly over 2–4 weeks with predominant proximal weakness [113]. Progression of neuropathy with affection of the nerves innervating respiratory muscles may lead to respiratory failure [112]. Porphyrias may respond to application of siRNA in the form of givosiran.

Lysosomal disorders

Lysosomal storage disorders (LSDs) predominantly affect the brain but in some of the about 80 subtypes, neuropathy has been occasionally described. Since LSDs are rare conditions and neuropathy does not occur in all of them, neuropathy in LSDs are generally rare. LSDs in which neuropathy has been described include Schindler's disease [114], Ohtahara syndrome [115], metachromatic leucodystrophy [116], Fabry disease [117], hereditary β -mannosidosis [118], Krabbe disease [119], Sandhoff disease [120], Gaucher disease [121], Niemann-Pick disease type C [122], galactosialidosis [123], mucopolysaccharidosis [124], ceroid lipofuscinosis [125], and rarely Pompe disease [126]. In Tay-Sachs disease axonal neuropathy can be found in a quarter of patients. The most frequent of the LSDs with neuropathy is Fabry's disease. Though Fabry disease is rare, all other LSDs are even rarer and thus neuropathy in these other LSDs has orphan status.

Peroxisomal disorders

Peroxisomal disorders form a group of rare, multisystem metabolic disorders, which are generally classified as either due to impaired peroxisomal biogenesis (PBDs) or due to deficiency of a single

peroxisomal enzyme (Zellweger spectrum disorders). The prototype of PBDs is Zellweger syndrome, clinically characterised by hypotonia, developmental delay, neuropathy, facial dysmorphism, epilepsy, rhizomelia, abnormal calcification, hepatomegaly, and abnormal liver function. Neuropathy in Zellweger syndrome is not well characterised but in the majority of the cases it is of the axonal type. The most well-known of the Zellweger spectrum disorders are neonatal, X-linked adrenoleukodystrophy and Refsum's disease. Adrenoleukodystrophy is due to mutations in the *ABCD1* gene. Neuropathy in adrenoleukodystrophy is a slowly progressive, dying back axonopathy. Refsum disease is either due to mutations in *PHYH* (90%) or *PEX7* (10%). Neuropathy in Refsum disease is sensori-motor and of the axonal type [127]. Phytanic acid levels can be reduced by plasmapheresis or diet.

Other complex hereditary neuropathies

Complex, hereditary neuropathies occur in a number of other genetic conditions. These include Tangier's disease, TTR-amyloid neuropathy, progressive myoclonus epilepsy due to *SCARB2* gene mutations, cerebellar ataxia, neuropathy, and vestibular areflexia syndrome (CANVAS). CANVAS is clinically characterised by cerebellar ataxia (CA), vestibular areflexia (VA), and neuropathy (N). Vestibular loss is usually bilateral. The prevalence of CANVAS is estimated as 26/100000. Recently, a homozygous, intronic AAGGG-repeat expansion in *RFC1* was discovered as the cause of CANVAS [128]. TTR-amyloid neuropathy is a progressive, debilitating, systemic disease due to deposition of misfolded transthyretin protein in the endoneurium. Misfolding results from mutations in the *TTR*-gene. Early diagnosis is desirable as treatments (e.g. tafamidis, patisiran) are available that slow the progression of the disease. Early diagnosis, however, is hampered by mistaking clinical manifestations for CIDP, idiopathic axonal PNP, diabetic neuropathy, or AL amyloidosis. In endemic countries (Portugal, Japan, Sweden, Brazil) TTR amyloid neuropathy should be suspected in any patient with length-dependent SFN with autonomic dysfunction [129]. In non-endemic countries the disease may manifest with rapidly progressive, sensorimotor, axonal neuropathy or atypical CIDP [129]. Tangier disease is due mutations in *ABCA1*, encoding the ATP binding cassette transporter. The disease is characterised by deficiency of high-density lipoproteins (HDLs) and accumulation of cholesterol esters in various tissues [130]. Major clinical findings

include hypertrophic yellow-orange tonsils [131], hepatosplenomegaly, and neuropathy [132]. The disease course is either relapsing-remitting or chronic progressive. Neuropathy is motor and sensory. Distribution of neuropathy can be multifocal, focal, or distal symmetric [130]. Upon NCSs neuropathy is demyelinating with conduction blocks in 11% of the patients [130]. Another rare, complex neuropathy is Brown-Vialetto-Van Laere syndrome which is due to loss-of-function mutations in the riboflavin transporter genes *SLC52A2* or *SLC52A3* [133]. In addition to sensorimotor neuropathy, patients present with cranial nerve neuropathies, ataxia, optic atrophy, deafness, and respiratory insufficiency [133]. Patients respond favourably to supplementation with riboflavin [133]. For patients carrying *CBIC* or *MTHFR* mutations, hydroxy-cobalamin respectively folic acid may be beneficial. Patients carrying mutations in *PDXK* profit from supplementation with pyridoxal-phosphate [134].

CONCLUSIONS

Rare (orphan) neuropathies of peripheral nerves need to be studied not only to assess the true prevalence of these conditions but also to delineate similarities and differences concerning clinical presentation and genetic heterogeneity from other more frequent types of neuropathies and to discover etiology and pathophysiology. Diagnosis of orphan neuropathies can be improved by referring neuropathies of unknown etiology to a reference center. Diagnosis of hereditary neuropathies can be improved by application of advanced genetic testing methods as early as possible. Treatment of acquired neuropathies can be improved by accurate, early diagnosis. Among the hereditary neuropathies TTR-PNP, Fabry disease, and neuropathies due to mutations in the riboflavin transporter need to be detected as early as possible to provide available treatment as early as possible. Though rare neuropathies are challenging with regard to diagnosis, epidemiology, and treatment, we should nonetheless meet this challenge as it may help elucidating etiology, pathophysiology, range of clinical presentation, and potential treatment options for these conditions.

CONFLICTS OF INTEREST

There are no conflicts of interest.

FUNDING

No funding was received.

AUTHOR CONTRIBUTION

JF: design, literature search, discussion, first draft, critical comments.

All authors have read the journal's position on issues involved in ethical publication.

The authors have read the Journal's position on issues involved in ethical publication.

REFERENCES

- [1] Dyck P, Thomas PK. Peripheral Neuropathy. Elsevier, Saunders 4th Edition, eBook ISBN: 9781437713473, Hardcover ISBN: 9780721694917, 2005
- [2] Van Swieten Blog. Orphan diseases. <https://ub.meduniwien.ac.at/blog/?p=18295> [last accessed: January 2020]
- [3] <https://www.fda.gov/drugs/drug-information-consumers/orphan-products-hope-people-rare-diseases>
- [4] Kuwabara S. Peripheral nerve disorders as common diseases. *Brain Nerve*. 2013;65:1071-5.
- [5] Burns TM, Mauermann ML. The evaluation of polyneuropathies. *Neurology*. 2011;76(7 suppl 2):S6-13.
- [6] Inês M, Coelho T, Conceição I, Duarte-Ramos F, de Carvalho M, Costa J. Epidemiology of Transthyretin Familial Amyloid Polyneuropathy in Portugal: A Nationwide Study. *Neuroepidemiology*. 2018;51:177-82.
- [7] Kato-Motozaki Y, Ono K, Shima K, Morinaga A, Machiya T, Nozaki I, Shibata-Hamaguchi A, Furukawa Y, Yanase D, Ishida C, Sakajiri K, Yamada M. Epidemiology of familial amyloid polyneuropathy in Japan: Identification of a novel endemic focus. *J Neurol Sci*. 2008;270:133-40.
- [8] Sousa A, Andersson R, Drugge U, Holmgren G, Sandgren O. Familial amyloidotic polyneuropathy in Sweden: Geographical distribution, age of onset, and prevalence. *Hum Hered*. 1993;43:288-94.
- [9] Siao P, Kaku M. A Clinician's Approach to Peripheral Neuropathy. *Semin Neurol*. 2019;39:519-30.
- [10] Carroll AS, Burns J, Nicholson G, Kiernan MC, Vucic S. Inherited Neuropathies. *Semin Neurol*. 2019;39:620-39.
- [11] Gwathmey KG, Grogan J. Nutritional neuropathies. *Muscle Nerve*. 2019. doi: 10.1002/mus.26783
- [12] Sharma S, Tobin V, Vas PRJ, Rayman G. The LDIFLARE and CCM Methods Demonstrate Early Nerve Fiber Abnormalities in Untreated Hypothyroidism: A Prospective Study. *J Clin Endocrinol Metab*. 2018;103:3094-102.
- [13] Jin PH, Shin SC. Neuropathy of Connective Tissue Diseases and Other Systemic Diseases. *Semin Neurol*. 2019;39:651-68.
- [14] Al-Wahaibi AK, Kumar S, Al-Risi A, Wali F. Thyrotoxic Neuropathy: A rare cause of acute flaccid paraplegia. *Sultan Qaboos Univ Med J*. 2017;17:e460-e463. doi:10.18295/squmj.2017.17.04.014
- [15] England JD, Gronseth GS, Franklin G, Carter GT, Kissel SJ, Cohen JA, Asbury AK, Szigeti K, Lupski JR, Latov N, Lewis RA, Low PA, Fisher MA, Herrmann DN, Howard JF Jr, Lauria G, Miller RG, Polydefkis M, Sumner AJ; American Academy of Neurology. Practice Param-

- ter: Evaluation of distal symmetric polyneuropathy: Role of laboratory and genetic testing (an evidence-based review). Report of the American Academy of Neurology, American Association of Neuromuscular and Electrodiagnostic Medicine, and American Academy of Physical Medicine and Rehabilitation. *Neurology*. 2009;72:185-92.
- [16] Saperstein DS, Wolfe GI, Gronseth GS, Nations SP, Herbelin LL, Bryan WW, Barohn RJ. Challenges in the identification of cobalamin-deficiency polyneuropathy. *Arch Neurol*. 2003;60:1296-301.
- [17] Levine TD, Saperstein DS. Laboratory evaluation of peripheral neuropathy. *Neurol Clin*. 2013;31:363-76.
- [18] Koike H, Takahashi M, Ohyama K, Hashimoto R, Kawagashira Y, Iijima M, Katsuno M, Doi H, Tanaka F, Sobue G. Clinicopathologic features of folate-deficiency neuropathy. *Neurology*. 2015;84:1026-33.
- [19] Huan MC. Laboratory evaluation of peripheral neuropathy. *Semin Neurol*. 2010;30:337-49.
- [20] Sechi G, Fois C, Addis A, Sechi E. Clinicopathologic features of folate-deficiency neuropathy. *Neurology*. 2015;85:1090-1.
- [21] Shible AA, Ramadurai D, Gergen D, Reynolds PM. Dry Beriberi Due to Thiamine Deficiency Associated with Peripheral Neuropathy and Wernicke's Encephalopathy Mimicking Guillain-Barré syndrome: A Case Report and Review of the Literature. *Am J Case Rep*. 2019;20:330-4.
- [22] Kulkantrakorn K. Pyridoxine-induced sensory ataxic neuropathy and neuropathy: Revisited. *Neurol Sci*. 2014;35:1827-30.
- [23] Moriwaki K, Kanno Y, Nakamoto H, Okada H, Suzuki H. Vitamin B6 deficiency in elderly patients on chronic peritoneal dialysis. *Adv Perit Dial*. 2000;16:308-12.
- [24] Wysota B, Michael S, Hiew FL, Dawson C, Rajabally YA. Severe but reversible neuropathy and encephalopathy due to vitamin E deficiency. *Clin Neurol Neurosurg*. 2017;160:19-20.
- [25] Rohm CL, Acree S, Lovett L. Progressive myeloneuropathy with symptomatic anaemia. *BMJ Case Rep*. 2019;12. pii: e230025. doi: 10.1136/bcr-2019-230025
- [26] Rapoport Y, Lavin PJ. Nutritional Optic Neuropathy Caused by Copper Deficiency After Bariatric Surgery. *J Neuroophthalmol*. 2016;36:178-81.
- [27] Stetkarova I, Bocek V, Gismatullina A, Svobodova Z, Peisker T. Severe chronic lithium intoxication in patient treated for bipolar disorder. *Neuro Endocrinol Lett*. 2017;38:397-400.
- [28] Chan CH, Leung AK, Cheung YF, Chan PY, Yeung KW, Lai KY. A rare neurological complication due to lithium poisoning. *Hong Kong Med J*. 2012;18:343-5.
- [29] Thomson RM, Parry GJ. Neuropathies associated with excessive exposure to lead. *Muscle Nerve*. 2006;33:732-41.
- [30] Helmich F, Lock G. Burton's Line from Chronic Lead Intoxication. *N Engl J Med*. 2018;379:e35.
- [31] Valappil AV, Mammen A. Subacute Arsenic Neuropathy: Clinical and Electrophysiological Observations. *J Neurosci Rural Pract*. 2019;10:529-32.
- [32] Hoitsma E, Marziniak M, Faber CG, Reulen JP, Sommer C, De Baets M, Drent M. Small fibre neuropathy in sarcoidosis. *Lancet*. 2002;359:2085-6.
- [33] Pelayo-de Tomás JM, Novoa-Parra C, Gómez-Barbero P. Cobalt toxicity after revision total hip replacement due to fracture of a ceramic head. *Rev Esp Cir Ortop Traumatol*. 2017;61:203-7.
- [34] Al-Kuraishy HM, Al-Gareeb AI, Hussien NR, Al-Naimi MS, Rasheed HA. Statins an oft-prescribed drug is implicated in peripheral neuropathy: The time to know more. *J Pak Med Assoc*. 2019;69(suppl 3):S108-S112.
- [35] Ghavanini AA, Kimpinski K. Revisiting the evidence for neuropathy caused by pyridoxine deficiency and excess. *J Clin Neuromuscul Dis*. 2014;16:25-31.
- [36] Vanta OM, Tohanean N, Pintea S, Perju-Dumbrava L. Large-Fiber Neuropathy in Parkinson's Disease: Clinical, Biological, and Electroneurographic Assessment of a Romanian Cohort. *J Clin Med*. 2019;24:8(10).
- [37] Romagnolo A, Merola A, Artusi CA, Rizzone MG, Zibetti M, Lopiano L. Levodopa-Induced Neuropathy: A Systematic Review. *Mov Disord Clin Pract*. 2018;6:96-103.
- [38] Islam B, Lustberg M, Staff NP, Kolb N, Alberti P, Argyriou AA. Vinca alkaloids, thalidomide and eribulin-induced peripheral neurotoxicity: From pathogenesis to treatment. *J Peripher Nerv Syst*. 2019;24(suppl 2):S63-S73.
- [39] de Greef BTA, Hoeijmakers JGJ, Gorissen-Brouwers CML, Geerts M, Faber CG, Merkies ISJ. Associated conditions in small fiber neuropathy - a large cohort study and review of the literature. *Eur J Neurol*. 2018;25:348-55.
- [40] Hersch MI, McLeod JG, Satchell PM, Early RG, Sullivan CE. Breathing pattern, lung inflation reflex and airway tone in acrylamide neuropathy. *Respir Physiol*. 1989;76:257-76.
- [41] Anand P, Kharal GA, Reda H, Venna N. Peripheral Neuropathies in Infectious Diseases. *Semin Neurol*. 2019;39:640-50.
- [42] Malek E, Salameh J. Guillain-Barre Syndrome. *Semin Neurol*. 2019;39:589-95.
- [43] Yuki N, Chan AC, Wong AHY, Inoue T, Yokai M, Kurihara T, Devaux JJ, Wilder-Smith E. Acute painful autoimmune neuropathy: A variant of Guillain-Barré syndrome. *Muscle Nerve*. 2018;57:320-4.
- [44] Bourque PR, Chardon JW, Massie R. Autoimmune peripheral neuropathies. *Clin Chim Acta*. 2015;449:37-42.
- [45] Hao Y, Wang W, Jacobs BC, Qiao B, Chen M, Liu D, Feng X, Wang Y. Antecedent infections in Guillain-Barré syndrome: A single-center, prospective study. *Ann Clin Transl Neurol*. 2019;6(12):2510-7.
- [46] Dev N, Kumar R, Kumar D. Guillain-Barre syndrome: A rare complication of leptospirosis and scrub typhus coinfection. *Trop Doct*. 2019;49:248-9.
- [47] Hameed S, Khan S. Rare variant of Guillain-Barré syndrome after chikungunya viral fever. *BMJ Case Rep*. 2019;12. pii: e228845. doi: 10.1136/bcr-2018-228845
- [48] Rivera-Correa J, de Siqueira IC, Mota S, do Rosário MS, Pereira de Jesus PA, Alcantara LCJ, Ernst JD, Rodríguez A. Anti-ganglioside antibodies in patients with Zika virus infection-associated Guillain-Barré Syndrome in Brazil. *PLoS Negl Trop Dis*. 2019;13(9):e0007695. doi: 10.1371/journal.pntd.0007695
- [49] Shah PM, Dhakre VW, Veerasuri R, Bhabhor A. Dysautonomia and hyponatraemia as harbingers of Guillain-Barre syndrome. *BMJ Case Rep*. 2019;12(4). pii: e226925. doi: 10.1136/bcr-2018-226925
- [50] Chang HW, Yang PY, Han TI, Meng NH. Wernicke encephalopathy concurrent with polyradiculoneuropathy in a young man after bariatric surgery: A case report. *Medicine (Baltimore)*. 2019;98(10):e14808. doi: 10.1097/MD.00000000000014808
- [51] Ding L, Chen Z, Sun Y, Bao H, Wu X, Zhong L, Zhang P, Lin Y, Liu Y. Guillain-Barré syndrome following bacte-

- rial meningitis: A case report and literature review. *BMC Neurol.* 2018;18:208. doi: 10.1186/s12883-018-1211-4
- [52] Shije J, Brannagan TH 3rd. Chronic Inflammatory Demyelinating Polyradiculoneuropathy. *Semin Neurol.* 2019;39:596-607.
- [53] Doppler K, Schuster Y, Appeltshausler L, Biko L, Villmann C, Weishaupt A, Werner C, Sommer C. Anti-CNTN1 IgG3 induces acute conduction block and motor deficits in a passive transfer rat model. *J Neuroinflammation.* 2019;16:73. doi: 10.1186/s12974-019-1462-z
- [54] Sekiguchi N, Hamano A, Kitagawa T, Kurihara Y, Ito K, Kurimoto M, Watanabe K, Hirano K, Noto S, Yamada K, Takezako N. Impact of rituximab and half-dose CHOP as primary therapy for untreated symptomatic Waldenström Macroglobulinemia: Review of a combined regimen of rituximab with an alkylating agent. *Blood Res.* 2018;53:117-22.
- [55] Torrealba-Acosta G, Gadhia R, Leslie-Mazwi T. A rare neurological complication of Waldenström's Macroglobulinemia. *J Clin Neurosci.* 2018;48:143-6.
- [56] Nakaseko C. POEMS syndrome: Advances in molecular pathophysiology and treatment. *Rinsho Ketsueki.* 2019;60:979-87.
- [57] Byun JM, Kwon YN, Koh Y, Yoon SS, Sung JJ, Kim I. Distinctive patterns of peripheral neuropathy across the spectrum of plasma cell disorders. *Sci Rep.* 2019;9:16769. doi: 10.1038/s41598-019-53289-w
- [58] Hamedani AG, Bird SJ, Tamhankar MA. CANOMAD Presenting as Bilateral Sixth Nerve Palsies. *J Neuroophthalmol.* 2019;39:397-8.
- [59] Garcia-Santibanez R, Zaidman CM, Sommerville RB, Lopate G, Wehl CC, Pestronk A, Bucelli RC. CANOMAD and other chronic ataxic neuropathies with disialosyl antibodies (CANADA). *J Neurol.* 2018;265:1402-9.
- [60] Boussaïd I, Bouhour F, Vial C, Caudie C. Identification and characterization of a monoclonal IgM reacting with disialylated gangliosides recognizing the CANOMAD syndrome. *Ann Biol Clin (Paris).* 2011;69:476-80.
- [61] Delmont E, Jeandel PY, Hubert AM, Marcq L, Boucraut J, Desnuelle C. Successful treatment with rituximab of one patient with CANOMAD neuropathy. *J Neurol.* 2010;257:655-7.
- [62] McKelvie PA, Gates PC, Day T. Canomad: Report of a case with a 40-year history and autopsy. Is this a sensory ganglionopathy with neuromuscular junction blockade? *Muscle Nerve.* 2013;48:599-603.
- [63] Beachy N, Satkowiak K, Gwathmey KG. Vasculitic Neuropathies. *Semin Neurol.* 2019;39:608-19.
- [64] Bischof A, Jaeger VK, Hadden RDM, Luqmani RA, Pröbstel AK, Merkel PA, Suppiah R, Craven A, Collins MP, Daikeler T. Peripheral neuropathy in antineutrophil cytoplasmic antibody-associated vasculitides: Insights from the DCVAS study. *Neurol Neuroimmunol Neuroinflamm.* 2019;6(6). pii: e615. doi: 10.1212/NXI.0000000000000615
- [65] Collins MP, Hadden RD. The nonsystemic vasculitic neuropathies. *Nat Rev Neurol.* 2017;13:302-16.
- [66] Jiménez-Ávila JM, Castañeda-Huerta JE, González-Cisneros AC. Bruns Garland syndrome. Report of a case and differential diagnosis with cauda equine syndrome. *Acta Ortop Mex.* 2019;33:42-5.
- [67] Barohn RJ, Sahenk Z, Warmolts JR, Mendell JR. The Bruns-Garland syndrome (diabetic amyotrophy). Revisited 100 years later. *Arch Neurol.* 1991;48:1130-5.
- [68] Mahmoud RA, Abrams CK. Acute demyelinating neuropathy in a patient with neurolymphomatosis. *BMJ Case Rep.* 2018;2018. pii: bcr-2017-222814. doi: 10.1136/bcr-2017-222814
- [69] Triplett JD, Khor TS, Kermode AG. Recurrent upper limb neuropathies secondary to an epithelioid haemangiopericytoma - A rare mimic of nerve tumours. *J Clin Neurosci.* 2019. pii: S0967-5868(18)32226-4.
- [70] Kesikburun S, Omac ÖK, Taşkınatan MA, Özgül A, Tan AK. Neoplastic brachial plexopathy detected by ultrasonography in a patient with chronic cervicobrachialgia. *J Rehabil Med.* 2012;44:181-3.
- [71] Gwathmey KG. Plexus and peripheral nerve metastasis. *Handb Clin Neurol.* 2018;149:257-79.
- [72] Antoine JC, Camdessanché JP. Paraneoplastic neuropathies. *Curr Opin Neurol.* 2017;30:513-20.
- [73] Koike H, Sobue G. Paraneoplastic neuropathy. *Handb Clin Neurol.* 2013;115:713-26.
- [74] Graus F, Dalmau J. Paraneoplastic neuropathies. *Curr Opin Neurol.* 2013;26:489-95.
- [75] Khan U, Warriach SA. Rare case: Paraneoplastic syndrome affecting peripheral nerves, associated with anti-collapsin-response mediator protein-5 (anti-CRMP5) antibodies, as early manifestation of small cell lung cancer confined to a solitary lymph node without evidence of lung mass on routine CT thorax. *BMJ Case Rep.* 2020;13(2). pii: e232656. doi: 10.1136/bcr-2019-232656
- [76] Eggermann K, Gess B, Häusler M, Weis J, Hahn A, Kurth I. Hereditary Neuropathies. *Dtsch Arztebl Int.* 2018;115:91-7.
- [77] Fridman V, Bundy B, Reilly MM, Pareyson D, Bacon C, Burns J, Day J, Feely S, Finkel RS, Grider T, Kirk CA, Herrmann DN, Laurá M, Li J, Lloyd T, Sumner CJ, Muntoni F, Piscosquito G, Ramchandren S, Shy R, Siskind CE, Yum SW, Moroni I, Pagliano E, Zuchner S, Scherer SS, Shy ME; Inherited Neuropathies Consortium. CMT subtypes and disease burden in patients enrolled in the Inherited Neuropathies Consortium natural history study: A cross-sectional analysis. *J Neurol Neurosurg Psychiatry.* 2015;86:873-8.
- [78] Linnemann C, Tezenas du Montcel S, Rakowicz M, Schmitz-Hübisch T, Szymanski S, Berciano J, van de Warrenburg BP, Pedersen K, Depondt C, Rola R, Klockgether T, García A, Mutlu G, Schöls L. Peripheral Neuropathy in Spinocerebellar Ataxia Type 1, 2, 3, and 6. *Cerebellum.* 2016;15:165-73.
- [79] Braathen GJ. Genetic epidemiology of Charcot-Marie-Tooth disease. *Acta Neurol Scand Suppl.* 2012;193:iv-22.
- [80] Dohrn MF, Glöckle N, Mulahasanovic L, Heller C, Mohr J, Bauer C, Riesch E, Becker A, Battke F, Hörtnagel K, Hornemann T, Suriyanarayanan S, Blankenburg M, Schulz JB, Claeys KG, Gess B, Katona I, Ferbert A, Vittore D, Grimm A, Wolkong S, Schöls L, Lerche H, Korenke GC, Fischer D, Schrank B, Kotzaeridou U, Kurlmann G, Dräger B, Schirmacher A, Young P, Schlotter-Weigel B, Biskup S. Frequent genes in rare diseases: Panel-based next generation sequencing to disclose causal mutations in hereditary neuropathies. *J Neurochem.* 2017;143:507-22.
- [81] Wang Z, Lin J, Qiao K, et al. Novel mutations in HINT1 gene cause the autosomal recessive axonal neuropathy with neuromyotonia. *Eur J Med Genet.* 2019;62(3):190-4. doi:10.1016/j.ejmg.2018.07.009
- [82] Skott H, Muntean-Firanesco C, Samuelsson K, Verrecchia L, Svenningsson P, Malmgren H, Cananau C, Espay AJ, Press R, Solders G, Paucar M. The cerebellar phenotype

- of Charcot-Marie-Tooth neuropathy type 4C. *Cerebellum Ataxias*. 2019;6:9. doi: 10.1186/s40673-019-0103-8
- [83] Echaniz-Laguna A, Cuisset JM, Guyant-Marchal L, Aubourg P, Kremer L, Baaloul N, Verloes A, Beladgham K, Perrot J, Francou B, Latour P. Giant axonal neuropathy: A multicenter retrospective study with genotypic spectrum expansion. *Neurogenetics*. 2019. doi: 10.1007/s10048-019-00596-z
- [84] Armao D, Bouldin TW, Bailey RM, Hooper JE, Bharucha DX, Gray SJ. Advancing the pathologic phenotype of giant axonal neuropathy: Early involvement of the ocular lens. *Orphanet J Rare Dis*. 2019;14:27. doi: 10.1186/s13023-018-0957-5
- [85] Pareyson D, Solari A, Taroni F, Botti S, Fallica E, Scaiola V, Ciano C, Sghirlanzoni A. Detection of hereditary neuropathy with liability to pressure palsies among patients with acute painless mononeuropathy or plexopathy. *Muscle Nerve*. 1998;21:1686-91.
- [86] Stögbauer F, Young P, Kerschensteiner M, Ringelstein EB, Assmann G, Funke H. Recurrent brachial plexus palsies as the only clinical expression of hereditary neuropathy with liability to pressure palsies associated with a de novo deletion of the peripheral myelin protein-22 gene. *Muscle Nerve*. 1998;21:1199-201.
- [87] Serin HM, Yılmaz S, Kanmaz S, Şimşek E, Aktan G, Tekgül H, Gökben S. A rare cause of brachial plexopathy: Hereditary neuralgic amyotrophy. *Turk Pediatr Ars*. 2019;54:189-91.
- [88] Kuhlenbäumer G, Hannibal MC, Nelis E, Schirmacher A, Verpoorten N, Meuleman J, Watts GD, De Vriendt E, Young P, Stögbauer F, Halfter H, Irobi J, Goossens D, Del-Favero J, Betz BG, Hor H, Kurlemann G, Bird TD, Airaksinen E, Mononen T, Serradell AP, Prats JM, Van Broeckhoven C, De Jonghe P, Timmerman V, Ringelstein EB, Chance PF. Mutations in SEPT9 cause hereditary neuralgic amyotrophy. *Nat Genet*. 2005;37:1044-6.
- [89] Zhou L. Small Fiber Neuropathy. *Semin Neurol*. 2019;39:570-7.
- [90] Suriyanarayanan S, Auranen M, Toppila J, Paetau A, Shcherbii M, Palin E, Wei Y, Lohioja T, Schlotter-Weigel B, Schön U, Abicht A, Rautenstrauss B, Tynismaa H, Walter MC, Hornemann T, Ylikallio E. The Variant p.(Arg183Trp) in SPTLC2 Causes Late-Onset Hereditary Sensory Neuropathy. *Neuromolecular Med*. 2016;18:81-90.
- [91] Luigetti M, Primiano G, Cuccagna C, Bernardo D, Sauchelli D, Vollono C, Servidei S. Small fibre neuropathy in mitochondrial diseases explored with sudoscan. *Clin Neurophysiol*. 2018;129:1618-23.
- [92] Cazzato D, Lauria G. Small fibre neuropathy. *Curr Opin Neurol*. 2017;30:490-9.
- [93] Claeys KG, Abicht A, Häusler M, Kleinle S, Wiesmann M, Schulz JB, Horvath R, Weis J. Novel genetic and neuropathological insights in neurogenic muscle weakness, ataxia, and retinitis pigmentosa (NARP). *Muscle Nerve*. 2016;54:328-33.
- [94] Rawle MJ, Lerner AJ. NARP Syndrome: A 20-Year Follow-Up. *Case Rep Neurol*. 2013;5:204-7.
- [95] Falcão de Campos C, Oliveira Santos M, Roque R, Conceição I, de Carvalho M. Mitochondrial Neurogastrointestinal Encephalomyopathy: Novel Pathogenic Mutation in Thymidine Phosphorylase Gene in a Patient from Cape Verde Islands. *Case Rep Neurol Med*. 2019;2019:5976410. doi: 10.1155/2019/5976410
- [96] Gáti I, Danielsson O, Jonasson J, Landtblom AM. Sensory ataxic neuropathy with dysarthria/dysphagia and ophthalmoplegia (SANDO). Two case reports. *Acta Myol*. 2011;30:188-90.
- [97] Hanisch F, Kornhuber M, Alston CL, Taylor RW, Deschauer M, Zierz S. SANDO syndrome in a cohort of 107 patients with CPEO and mitochondrial DNA deletions. *J Neurol Neurosurg Psychiatry*. 2015;86:630-4.
- [98] Wong LJ, Naviaux RK, Brunetti-Pierri N, Zhang Q, Schmitt ES, Truong C, Milone M, Cohen BH, Wical B, Ganesh J, Basinger AA, Burton BK, Swoboda K, Gilbert DL, Vanderver A, Saneto RP, Maranda B, Arnold G, Abdenur JE, Waters PJ, Copeland WC. Molecular and clinical genetics of mitochondrial diseases due to POLG mutations. *Hum Mutat*. 2008;29:E150-72.
- [99] Luigetti M, Sauchelli D, Primiano G, Cuccagna C, Bernardo D, Lo Monaco M, Servidei S. Peripheral neuropathy is a common manifestation of mitochondrial diseases: A single-centre experience. *Eur J Neurol*. 2016;23:1020-7.
- [100] Finsterer J. Mitochondrial neuropathy. *Clin Neurol Neurosurg*. 2005;107:181-6.
- [101] Horga A, Pitceathly RD, Blake JC, Woodward CE, Zapater P, Fratter C, Mudanohwo EE, Plant GT, Houlden H, Sweeney MG, Hanna MG, Reilly MM. Peripheral neuropathy predicts nuclear gene defect in patients with mitochondrial ophthalmoplegia. *Brain*. 2014;137:3200-12.
- [102] Finsterer J, Löscher W, Quasthoff S, Wanschitz J, Auer-Grumbach M, Stevanin G. Hereditary spastic paraplegias with autosomal dominant, recessive, X-linked, or maternal trait of inheritance. *J Neurol Sci*. 2012;318:1-18.
- [103] Scott P, Al Kindi A, Al Fahdi A, Al Yarubi N, Bruwer Z, Al Adawi S, Nandhagopal R. Spinocerebellar ataxia with axonal neuropathy type 1 revisited. *J Clin Neurosci*. 2019;67:139-44.
- [104] Pelosi L, Iodice R, Antenora A, Kilfoyle D, Mulroy E, Rodrigues M, Roxburgh R, Iovino A, Filla A, Manganelli F, Santoro L. Spinocerebellar ataxia type 2-neuronopathy or neuropathy? *Muscle Nerve*. 2019;60:271-8.
- [105] Paulson H. Spinocerebellar Ataxia Type 3. 1998 Oct 10 [updated 2015 Sep 24]. In: Adam MP, Ardinger HH, Pagon RA, Wallace SE, Bean LJH, Stephens K, Amemiya A, editors. *GeneReviews*® [Internet]. Seattle (WA): University of Washington, Seattle; 1993-2020. Available from <http://www.ncbi.nlm.nih.gov/books/NBK1196/>
- [106] Hellenbroich Y, Bubel S, Pawlack H, Opitz S, Vieregge P, Schwinger E, Zühlke C. Refinement of the spinocerebellar ataxia type 4 locus in a large German family and exclusion of CAG repeat expansions in this region. *J Neurol*. 2003;250:668-71.
- [107] Salas-Vargas J, Mancera-Gervacio J, Velázquez-Pérez L, Rodríguez-Labrada R, Martínez-Cruz E, Magaña JJ, Durand-Rivera A, Hernández-Hernández O, Cisneros B, Gonzalez-Piña R. Spinocerebellar ataxia type 7: A neurodegenerative disorder with peripheral neuropathy. *Eur Neurol*. 2015;73:173-8.
- [108] Matsuura T, Ashizawa T. Spinocerebellar Ataxia Type 10. 2002 Apr 23 [updated 2019 Sep 19]. In: Adam MP, Ardinger HH, Pagon RA, Wallace SE, Bean LJH, Stephens K, Amemiya A, editors. *GeneReviews*® [Internet]. Seattle (WA): University of Washington, Seattle; 1993-2020. Available from <http://www.ncbi.nlm.nih.gov/books/NBK1175/>
- [109] Chen Z, Puzriakova A, Houlden H. Spinocerebellar Ataxia Type 11. 2008 Jul 22 [updated 2019 Oct 31]. In: Adam MP, Ardinger HH, Pagon RA, Wallace SE, Bean LJH, Stephens K, Amemiya A,

- editors. GeneReviews® [Internet]. Seattle (WA): University of Washington, Seattle; 1993-2020. Available from <http://www.ncbi.nlm.nih.gov/books/NBK1757/>
- [110] Lin P, Zhang D, Xu G, Yan C. Identification of IFRD1 variant in a Han Chinese family with autosomal dominant hereditary spastic paraplegia associated with peripheral neuropathy and ataxia. *J Hum Genet.* 2018;63:521-4.
- [111] Nanetti L, Cavalieri S, Pensato V, Erbetta A, Pareyson D, Panzeri M, Zorzi G, Antozzi C, Moroni I, Gellera C, Brusco A, Mariotti C. SETX mutations are a frequent genetic cause of juvenile and adult onset cerebellar ataxia with neuropathy and elevated serum alpha-fetoprotein. *Orphanet J Rare Dis.* 2013;8:123. doi: 10.1186/1750-1172-8-123
- [112] Edel Y, Mamet R. Porphyria: What Is It and Who Should Be Evaluated? *Rambam Maimonides Med J.* 2018;9(2). doi: 10.5041/RMMJ.10333
- [113] O'Malley R, Rao G, Stein P, Bandmann O. Porphyria: Often discussed but too often missed. *Pract Neurol.* 2018;18:352-8.
- [114] Castro RG, Pérez AMG, Curto MCR, Álvarez JC, Ferreira AC, Cuadros AV, Bueno DM, Fernández AJC. A New Case of Schindler Disease. *Eur J Case Rep Intern Med.* 2019;6(11):001269. doi: 10.12890/2019.001269
- [115] Esposito A, Falace A, Wagner M, Gal M, Mei D, Conti V, Pisano T, Aprile D, Cerullo MS, De Fusco A, Giovedì S, Seibt A, Magen D, Polster T, Eran A, Stenton SL, Fiorillo C, Ravid S, Mayatepek E, Hafner H, Wortmann S, Levanon EY, Marini C, Mandel H, Benfenati F, Distelmaier F, Fassio A, Guerrini R. Biallelic DMXL2 mutations impair autophagy and cause Ohtahara syndrome with progressive course. *Brain.* 2019;142:3876-91.
- [116] Beerepoot S, Nierkens S, Boelens JJ, Lindemans C, Bugiani M, Wolf NI. Peripheral neuropathy in metachromatic leukodystrophy: Current status and future perspective. *Orphanet J Rare Dis.* 2019;14:240. doi: 10.1186/s13023-019-1220-4
- [117] Varela P, Mastroianni Kirsztajn G, Ferrer H, Aranda C, Wallbach K, Ferreira da Mata G, Moura LA, Moreira SR, Mendes C, Curiati MA, Martins AM, Bosco Pesquero J. Functional Characterization and Pharmacological Evaluation of a Novel GLA Missense Mutation Found in a Severely Affected Fabry Disease Family. *Nephron.* 2019;1-9. doi: 10.1159/000503998
- [118] Bolfa P, Wang P, Nair R, Rajeev S, Armién AG, Henthorn PS, Wood T, Thrall MA, Giger U. Hereditary β -mannosidosis in a dog: Clinicopathological and molecular genetic characterization. *Mol Genet Metab.* 2019;128:137-43.
- [119] Nashabat M, Al-Khenaizan S, Alfadhel M. Report of a Case that Expands the Phenotype of Infantile Krabbe Disease. *Am J Case Rep.* 2019;20:643-6.
- [120] Grunseich C, Schindler AB, Chen KL, Bakar D, Mankodi A, Traslavina R, Ray-Chaudhury A, Lehky TJ, Baker EH, Maragakis NJ, Tiftt CJ, Fischbeck KH. Peripheral neuropathy in a family with Sandhoff disease and SH3TC2 deficiency. *J Neurol.* 2015;262:1066-8.
- [121] Andréasson M, Solders G, Björkqvall CK, Machaczka M, Svenningsson P. Polyneuropathy in Gaucher disease type 1 and 3 - a descriptive case series. *Sci Rep.* 2019;9:15358. doi:10.1038/s41598-019-51976-2
- [122] Zafeiriou DI, Triantafyllou P, Gombakis NP, Vargiami E, Tsantali C, Michelakaki E. Niemann-Pick type C disease associated with peripheral neuropathy. *Pediatr Neurol.* 2003;29:242-4.
- [123] Tan EK, Wong MC, Ng I, Teo SH, Lo YL, Cho MM. Unusual pure motor axonal neuropathy in a Burmese family with galactosialidosis. *J Inher Metab Dis.* 1998;21:869-70. doi:10.1023/a:1005431021025
- [124] Steet RA, Hullin R, Kudo M, et al. A splicing mutation in the alpha/beta GlcNAc-1-phosphotransferase gene results in an adult onset form of mucopolisaccharidosis III associated with sensory neuropathy and cardiomyopathy. *Am J Med Genet A.* 2005;132A:369-75. doi:10.1002/ajmg.a.30498
- [125] Wisniewski KE, Madrid RE, Damska M, Rapin I, Pullarkat R, Sklower S. Spino-cerebellar degeneration with polyneuropathy associated with ceroid lipofuscinosis in one family. *J Child Neurol.* 1988;3:33-41. doi:10.1177/088307388800300108
- [126] Lamartine S, Monteiro M, Rémicé G. Late-onset Pompe disease associated with polyneuropathy. *Neuromuscul Disord.* 2019;29:968-72. doi:10.1016/j.nmd.2019.08.016
- [127] Dasouki M. Peroxisomal disorders. In: *Biomarkers in Inborn Errors of Metabolism, 2017*
- [128] Cortese A, Tozza S, Yau WY, Rossi S, Beecroft SJ, Jaunmuktane Z, Dyer Z, Ravenscroft G, Lamont PJ, Mossman S, Chancellor A, Maisonnobe T, Pereon Y, Cauquil C, Colnaghi S, Mallucci G, Curro R, Tomaselli PJ, Thomas-Black G, Sullivan R, Efthymiou S, Rossor AM, Laurá M, Pipis M, Horga A, Polke J, Kaski D, Horvath R, Chinnery PF, Marques W, Tassorelli C, Devigili G, Leonardis L, Wood NW, Bronstein A, Giunti P, Züchner S, Stojkovic T, Laing N, Roxburgh RH, Houlden H, Reilly MM. Cerebellar ataxia, neuropathy, vestibular areflexia syndrome due to RFC1 repeat expansion. *Brain.* 2020;143:480-90.
- [129] Adams D, Ando Y, Beirão JM, Coelho T, Gertz MA, Gilmore JD, Hawkins PN, Lousada I, Suhr OB, Merlini G. Expert consensus recommendations to improve diagnosis of ATTR amyloidosis with polyneuropathy. *J Neurol.* 2020. doi: 10.1007/s00415-019-09688-0
- [130] Mercan M, Yayla V, Altınay S, Seyhan S. Peripheral neuropathy in Tangier disease: A literature review and assessment. *J Peripher Nerv Syst.* 2018;23:88-98. doi: 10.1111/jns.12265
- [131] Muratsu J, Koseki M, Masuda D, Yasuga Y, Tomoyama S, Ataka K, Yagi Y, Nakagawa A, Hamada H, Fujita S, Hattori H, Ohama T, Nishida M, Hiraoka H, Matsuzawa Y, Yamashita S. Accelerated Atherogenicity in Tangier Disease. *J Atheroscler Thromb.* 2018;25:1076-85.
- [132] Burnett JR, Hooper AJ, McCormick SPA, Hegele RA. Tangier Disease. 2019 Nov 21. In: Adam MP, Ardinger HH, Pagon RA, Wallace SE, Bean LJH, Stephens K, Amemiya A, editors. GeneReviews® [Internet]. Seattle (WA): University of Washington, Seattle; 1993-2019. Available from <http://www.ncbi.nlm.nih.gov/books/NBK549920/>
- [133] Manole A, Jaunmuktane Z, Hargreaves I, Ludtmann MHR, Salpietro V, Bello OD, Pope S, Pandraud A, Horga A, Scalco RS, Li A, Ashokkumar B, Lourenço CM, Heales S, Horvath R, Chinnery PF, Toro C, Singleton AB, Jacques TS, Abramov AY, Muntoni F, Hanna MG, Reilly MM, Revesz T, Kullmann DM, Jepsen JEC, Houlden H. Clinical, pathological and functional characterization of riboflavin-responsive neuropathy. *Brain.* 2017;140:2820-37.
- [134] Chelban V, Wilson MP, Warman Chardon J, et al. PDXK mutations cause polyneuropathy responsive to pyridoxal 5'-phosphate supplementation. *Ann Neurol.* 2019;86:225-40.